rheumatology

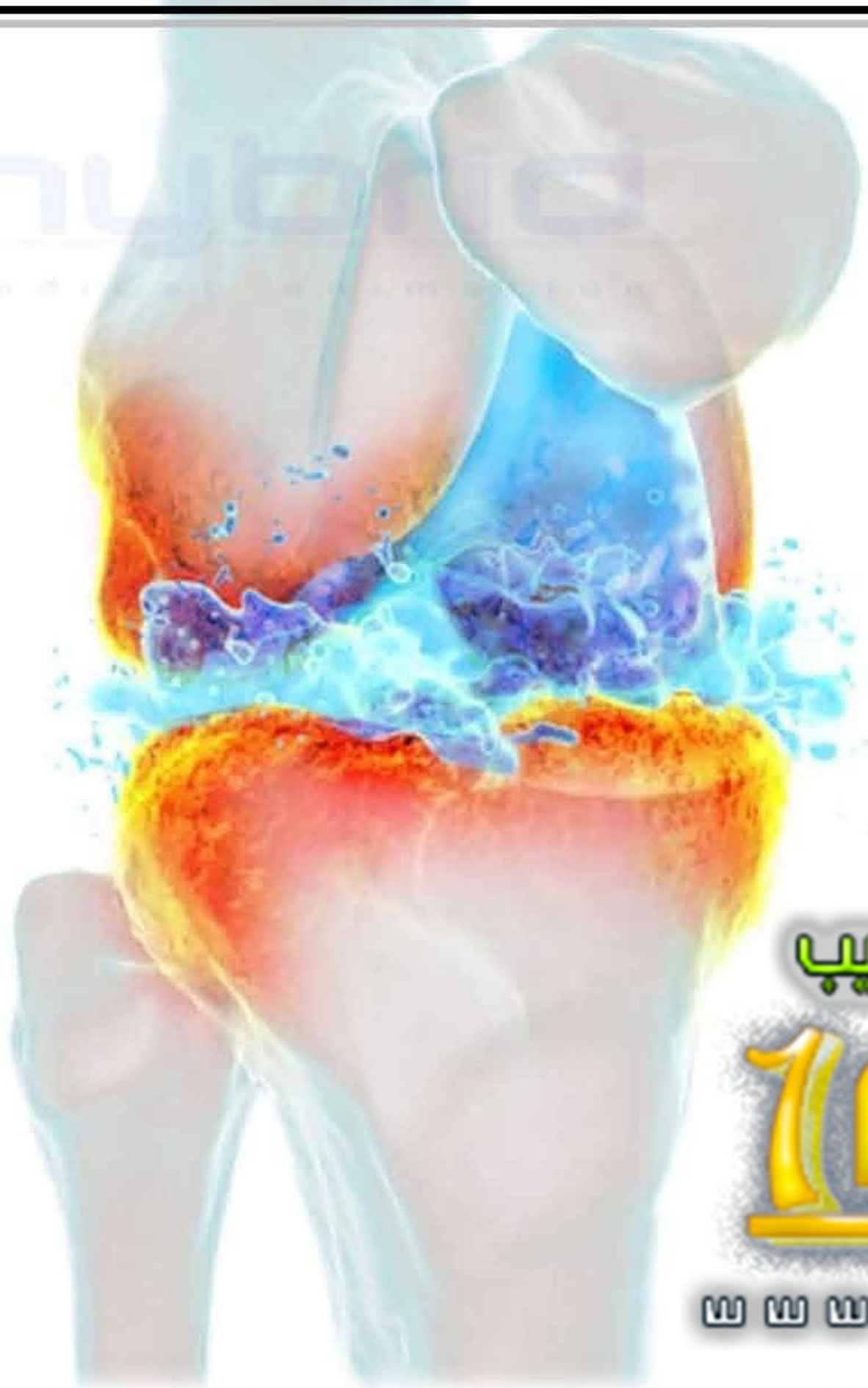

2009-2010

Index:

- SLE.
- Rheumatoid Arthritis.
- Poly Myositis & Dermatomyositis.
- Scleroderma.
- Spondylo-Arthropathy.
- Mixed CT D / Behcet's D.
- Vasculitis.
- Gout & hyper-uricemia.
- OA / SA / OM / OP.

Systemic Lupus Erythematosus	Rheumatoid Arthritis	Poly-Myositis Dermato-Myositis	Scleroderma "Systemic Sclerosis"
➢ Multi-systemic CT disease. ➢ Mainly Extra-Articular.	Multi-systemic CT disease M/C Chronic Inflam. Disease	Inflammatory Myopathy (lymphocytic infilt. of skeletal Ms. & Skin) Search for Malignancy in old age.	Multi-systemic CT disease ccc by: degeneration & Fibrosis of Skin & Viscera.
Auto-immune T-suppressor defect ⇓ ↑ B-cell prod. of auto-abs (↑γ Globulins) ⇓ Immune complex. (↓ Complement in blood) ⇓ Systemic manif. exposure to oxidative stress (UV – pregnancy – infection) ⇓ ↑ rate of apoptosis e expression of hidden Ags on CM ⇓ ⊕ T-cell ⇓ ⊕ B-cell Auto-AB production.	Un-known Triggering Ag → ⊕ Ig M RF. → Bind to altered Fc portion of Ig G. (it abnormal glycosylation) → Activation of Complement. → IC deposition in synovial memb. (↓ Complement in synovium while N. in blood) → release of Inflam. mediators & Cytokines Rh. Nodules = SC granuloma • On Tendon Sheath Extensor surface. • Biopsy … central fibrinoid necrosis surr. By PNL.	Auto-immune 1. 1ry Idiopathic. 2. 2ry to Malignancy para-malig. $ → Tumor Ag-Ab → IC. Mixed CT disease.	Vascular endothelial damage endothelin release ⇓ VC "Ischemia" ⇓ EAO ↓ Ch. ischemia cytokines & Growth F. (PDGF / TGF) ⇓ ⊕ Fibroblasts ↑↑ collagen & Fibronectin dep. in Skin & Viscera
➢ Sex	♀ > ♂ 9:1	♀ > ♂ 3:1	♀ > ♂ 3:1	♀ > ♂ 4:1
➢ Age	2nd – 3rd decade	any age "30-40 ys"	3rd – 6th decade	4th – 5th Decade
➢ PDF	1) Env. Triggers ? UV (Sun-light, artif.? 2) Drug Induced ⇒ Hydralizaine – Phenytoin. • CL /P → Drug history / equal sex. No nephritis or Cerebral D. • Invest. +ve ANA & Anti-Histone / -ve Anti-DNA • TTT. Stop drug + Steroids if sever. 3) Estrogen? OCP - HRT. • Exacerbation during pregnancy. • Common in child bearing period.	1) Auto-immune. 2) HLA – DR_4 3) Infection. (bact. / slow virus)?!! 4) Smoking.		

➢ Musculo-Skeletal

Systemic Lupus Eryth.

Joints ⇒ **Arthralgia = pain only**

- Bi-lateral & symmetrical.
- ***peripheral*** *joints mainly.*
- ***small*** *joints.*
- **non-erosive** *but* ***deformity*** *is due to laxaity of tendons & ligaments. (no articular damage)*

⇓

Jaccoud's Arthropathy

➢ **Bone** ⇒ *Avascular Necrosis in hip dt Steroid*
→ pain & Internal Rotation.

Pathology of SLE

1) Hx. Bodies. *(remnant of nuclear proteins)*
2) Silvery Wire app. *(lupus nephritis)*
3) Onion Skin. *(collagen deposition around Splenic a.)*

Rh. Arthritis

Joints ⇒ **Arthritis = pain + R H T S up to effusion**
↑Morning stiffness > 1 hr.

- Bi-lateral & symmetrical.
- ***peripheral*** *joints mainly.*
- ***small*** *joints.*
- ***erosive → deformity***
  a) ***PIP involved.***
  b) ***DIP spared.***

Hands ⇒ Dis-use Atrophy eg. Thenar & hypo-thenar ms.

- **Ulnar dev.** *At MCP Joint due to sub-laxation* → MC Squeeze
- **Swan Neck** → *flexion of DIP & extension of PIP.*
  dt teno-synovitis ***bec. DIP is spared in RA.***
- **Boutonnière** *(عكس اللفوق)*
- **Trigger finger.**
- **Z deformity** *of the thumb.*

Feet: *MTP Joint.* → *MT squeez.*

Cx spine: *atlanto-axial sub-laxation → cord compression → occipital headache → emergency.*

Elbow: flexion deformity.

Knee: *effusion in bursa of calf & semi-memb. ms.* ⇒ *tender swelling of the popliteal fossa* ⇒ ***(Baker's cyst)***

TMJ:

PM & DM

- **Joints** ⇒ **Arthralgia.**
- **Myopathy:**
  - Bi-lateral & symmetrical.
  - P not D.
  - ± Ms. Tender.
  - **Reflexes preserved.**
    (Myopathy عكس الـ)

DD of Myopathy

1) Duchene.
2) PMR
3) DM / PM

Scleroderma

Joints ⇒ **Arthralgia**

- Bi-lateral & symmetrical.
- ***peripheral*** *joints mainly.*
- ***small*** *joints.*
- **non-erosive**

Myopathy

➢ Cl. /P ⇒ Extra-Articular manif.

	Systemic Lupus Eryth.	Rh. Arthritis	PM & DM	Scleroderma
1) Skin اختلاف	**Fever of Unknown Origin** 1) **Butter fly rash:** fixed erythema (flat / raised) photo-sensitive dist, **s paring the NLF.** 2) **Discoid rash** ⇒ erythematous patches + scales. (if scalp ⇒ **cicatricial Alopecia**) 3) **Photosensitivity.** 4) **Purpuric eruptions:** • Thrombo-cytopenic → non-raised edge. • Vasculitis → raised edge. 5) **Lichen planus like.** **Urticaria.** 6) **Vasculitis** ⇒ nail bed infarcts. 7) **Reynaud's ph.** **Livedo-reticularis.**	**Fever of Unknown Origin** 1) **SC Rh. Nodules.** • **Tendon Sheath** in Oleorhandon bursa Achiles Tendon - Px. Ulna) • **Extensor Surface** E& Dorsum of Hand. 2) **Palmar Erythema** 3) **Reynaud's ph.** 4) **Vasculitis.** (if Vasculitis with +ve RF = RA presented e Vasculitis) **Palmar Erythema: Normal or..** • **RA.** **Alcohol.** • **Chronic LD** **Thyro-toxicosis.**	1) **Helio-tope Rash** "violaceous peri-orbital Rash" 2) **Reynaud's ph.** 3) **Gottron's papules** "papular rash with scales on the dorsa of hands & bony prominences"	1) **Reynaud's ph.** White → pallor e coldness Blue → Cyanosis dt VC Red → Rebound Erythema e pain & Tingling 2) **Non-pitting edema** dt collagen deposition **early** → Tight Skin of fingers px limbs – Thorax → restriction of mov **late** → shiny skin e atrophy → Ulceration → **hyper & hypo-pig. Area + Calcinosis**
2) Heart	**Pan-carditis + ↓BP** except in lupus nephritis ↑BP • Peri-carditis. (M/C) • Myocarditis ⇒ HF. • **Endocarditis** **Libman sacks (MI – AI)**	**Pan-carditis** ➢ **Aortitis** inflamed Aortic root ⇒ **AI.** ➢ **Vasculitis** ⇒ Coronary HD.	**Cardiomyopathy** ⇒ HF & Arrhythmias.	• **Peri-carditis & eff.** • **Cardio-myopathy** ⇒ HF • **Vasculitis** ⇒ Coronary HD.
3) Lung	➢ **Pleurisy - Pleural eff.** (pain in Axilla) ➢ **IPF** **P++** E Anti-phospholipid $ ➢ **Shrunken lung $** elevation of diaph. dt recurrent Multiple pulmonary infarction. ➢ **ARDS.**	➢ **Pleurisy - Pleural eff.** (↓C in RA/SLE/TB) ➢ **IPF** **P++** ➢ **Cryco-art. Arthritis** ⇒ HOARSENESS. ➢ **Rh. Nodule in lung*** ➢ **Caplan's $** ⇒ * + **Pneumo-coniosis.**	➢ **IPF**	➢ **IPF** **P++** ➢ **Aspiration Pneumonia** (DT ESOPH. DYSFUNCTION)

4) **GIT**	• **Mesenteric vasculitis** ⇒ VASCULAR OCC. ⇒ ACUTE ABDOMEN. • **Also dt Poly-Serositis..... 3Ps**		**DYSPHAGIA** *Due to Upper esoph. dysmotility.* ⇓ *(myositis of striated ms. in upper 1/3 of esoph.)*	• DYSPHAGIA ○ **GERD.** ○ **CONSTIP.** *e intestinal pseudo-obst.* ○ **MAL-ABS. $** *dt bact. over growth.* ○ **1RY BILIARY CIRRHOSIS** } ↓↓ **MOTILITY**
5) **Kidney** اختلاف	**Lupus Nephritis** **WHO classifications** *"young ♀ e proteinuria)*	**Nephrotic $ dt** **Drug induced GN** *NSAID. (Minimal lesion GN / Interstitial nephritis)* **Amyloidosis Kidney (M/C cause)**	**Malignancy E OLD MALE.**	**1) Scleroderma Kidney** *dt narrowing of inter-lobular a* *→ Ischemia → Malig. HTN → RF* **2) Sclerodermal Renal Crisis:** • SUDDEN HTN • OLIGURIA • μ ANGIOPATHIC HAEMOLYSIS.
6) **Eye**	• *Retinal infarction.* • *K-C sicca e Sjogren's $.*	• *Epi-scleritis – Scleritis.* • *K-C sicca e Sjogren's $.*		
7) **Blood**	**DT Auto-immune Abs** **a) ↓RBCs:** ○ *Normo-cytic / normo-chromic.* ○ *AIHA. (3 L)* **b) ↓WBCs** *Lymphopenia e activity.* **c) ↓PLATELETS** *e activity* ➢ **Anti-ph $ ⇒ Thrombo-Embolism...Repeated Abortions.**	**a) ↓RBCs:** ○ ***Normo*** *→ Chronic D.* ○ ***Micro → Iron def.*** *"NSAID induced Gastritis"* ○ ***Macro → Metho-treate.*** *"dt folic A. deficiency"* **b) ↑WBCs** *e activity.* *"no toxic granulation = no infection"* **a) ↑PLATELETS** *e activity* } ↓ *IN FELTY'S $* DT *HYPER-SPLENESM*		
8) **Neuro**	➢ **Psychosis – Depression.** **(DD e Steroid Induced Psychosis if > 40mg .... resolves when ↓ Steroid dose + Add Azathiprine)** ➢ **Chorea.** ➢ **PN** ➢ **Cerebral Vasculit → stroke.** **Similar to Rh. F in:** • Carditis. • Arthralgia. • Chorea. - Fever. **"so Depend on Recent**	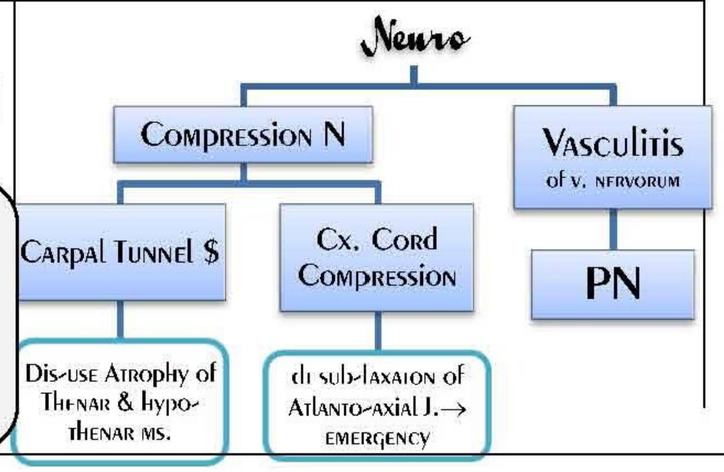		

	Systemic Lupus Eryth.	Rh. Arthritis	PM & DM	Scleroderma
Blood:	**a) ↓RBCs:** ○ Of Chronic diseas...Normo., ○ A / H A = 3 L ..+ve Coomb's te **b) ↓WBCs** Lymphopenia e activity. **c) ↓Platelets** e activity. **d) Anti-phospholipid Abs** 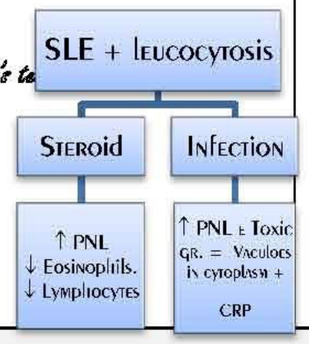 	**c) ↓RBCs:** ○ Of Chronic d. Normocytic normochromic. ○ Iron def. "NSAID → Gastritis → bl. loss." **d) ↑WBCs** e activity. **a) ↑Platelets** e activity } **↓ in Felty's Triad** Chronic RA. ↓ WBCs & Platelets DT Hyper-splenism	1) **EMG** ⇒ Myopathy. 2) **Ms. Biopsy** ⇒ guided by MRI from active inflamed ms..	**a) ↓RBCs:** μ angio-pathic Hemolytic An. DT collagen deposition vs. wall **b) Skin Biopsy** ⇒ collagen in dermis.
➢ **Markers Invest.**	1) **↑ESR & CRP normal** (but ↑ e infection). 2) **↓ C_3 & C_4** DT **↑ γ Globulinemia.** 3) +ve R F. 4) **Anti-smAb.** (Specific for SLE) 5) **ANA.** (Sn. but Non-Sp.) but Specificity ↑ e with ↑ Titre) Activity: ↑ESR - ↓ C_3,C_4 Anti-DNA 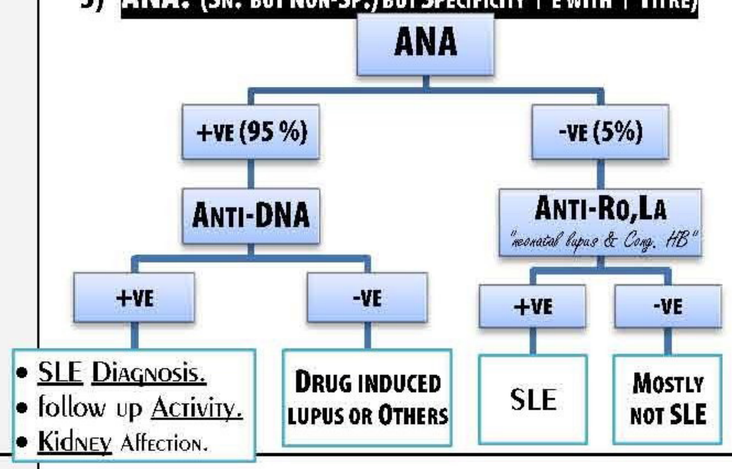 	1) **↑ESR & ↑CRP.** 2) **Normal Complement** in bl. (but ↓ in **Synovium**) ↓ Protein - Glucose. 3) +ve RF in 80% 4) +ve ANA 20% / -ve Anti-DNA. ↑ WBCs ⇒ Cloudy 5) **Anti-CCP** (V. Early Diagnosis if –ve RF) 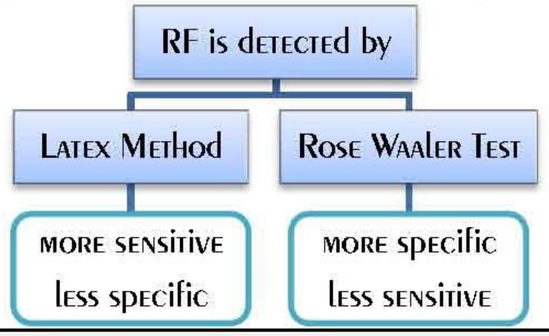 	1) **↑ESR** in 50%. 2) **↑CK** e activity (MM fraction) 3) +ve RF. 4) +ve ANA. 5) **Anti-Jo-1 "specific"**	➢ +ve RF. ➢ +ve ANA ➢ **Anti-Scl 70** (specific) (Auto-Ab against sclero-nuclear protein "Anti-topoisomerase)
➢ **Other Invest.**	1) **Kidney function** • Urine analysis. • Renal biopsy. NB: SLE in Pregnancy....p.13	**X-ray:** **Early** ✓ Soft t. swelling + Bony erosions ✓ Peri-Articular osteoporosis. ✓ Narrow j. space. (dt destruction of cartilage) **Late** ⇓ Ankylosis Deformity	Follow up by Ms. power	**X-ray:** A) **Ba Swallow** ⇒ impaired oesoph. motility. B) **Hand** ⇒ Ca around fingers e resion & **resorption** around the tuft of distal ph.

Systemic Lupus Eryth.

Advices: نصائح

1) Sun screen – protective clothes.
2) Avoid ⇒ OCP & (BB if PVD) give VD
3) Give ⇒ Aspirin for anti-ph lipi d S.

Symptomatic:

1) Arthralgia ⇒ NSAID ± Hydroxy-ch..
2) Skin ⇒ hydroxy-ch. + Topical Steroids.

Rh. Arthritis

Advices: نصائح

1) Rest in bed during acute exacerbation.
2) Splinting ⇒ ↓pain & deformity.
3) Physio-th. ⇒ After exacerb. disappears.

Symptomatic: Anti-inflam to Relief pain & doesn't (-) deformity

1) **NSAID** ⇒ (Piroxicam - Diclofenac - Ketoprufen)
   Nephro-toxic up to RF — Gastritis
   Anti-platelet → HGE. — BS.
2) **Steroids** (7.5 mg / d) + Proph. Against Osteo-prosis (Ca, Vit. D, Bis-phosph.)

PM & DM

Search for Neoplasm.

Intra-Articular Steroids:

- ✓ Osteo-Arthritis.
- ✓ Tenosynovitis.
- ✓ Carpel tunnel $.

Scleroderma

Symptomatic:

A) Dysphagia. ⇒ Metoclopramide.
B) Bacterial over growth ⇒ ABS.
C) HTN & Renal crisis ⇒ ACE-I.
D) P^+ & digital ulcer ⇒ Endothelin R-Antagonist. (Bosentan).
E) Raynaud's ph. ⇒ CCB or Nitro-glycrine ointment & # BB)
F) penicillamine ⇒ Skin Softening

Steroids القاعدة كاملة

If severe ⇓

Pulse Steroid th.

- Methyl Prednisolone.
- 500 - 1000 mg / day
- IV (3-5 days)
- Then (Steroids القاعدة)

Pulse Cyclo-phosph.

SLE e Cerebral
Presentric CN

- Endoxan.
- 0.5 – 0.75 gm
- IV (every month for 6ms.)
- Less S/E than Oral Endoxan.

Other uses of Pulse Steroid	Pre-cautions of Pulse Steroid
• severe SLE • MS – ON • RPGN. • Auto-immune ITP	• PU ⇒ PPI. • Control BP – Bl. sugar. • Isolation to avoid infection. • Avoid Osteoporosis = Ca^{++} + Vit. D

Plasma-pharesis. (in sever exacerbation)

1) DMARD

"taken for long period to ↓ progression ⇒ (-) Deformity"

a) **hydroxy-chloroquine:** "immune-modulator"
   - Dose: 200 mg/12 hr.
   - S/E: retinopathy → Fundus exam.

b) **(Methotrexate 7.5 mg / week + Steroid 7.5 mg / day)**
   S/E: Hepato-toxic + BM رائع هذا هو الاساس

c) Leflunomide. (Methotraxate but less BM (-) شبه الـ

d) Sulpha-salazine (Megalo-blastic An. → Give Folic A.)

e) Penicillamine / Gold (c. Nephro-toxic / BM (-)

f) Azathrioprine & Cyclo-sporin. (Toxic)

2) Biological ⇒ Anti-cytokine MCA used if DMARDs failed.

3) Surgical ⇒ Mechanical Aids.

Steroids القاعدة كاملة

If severe ⇓

E Respiratory or pharyngeal Weakness

Pulse Steroid th.

Steroids القاعدة كاملة

(If pleurisy or pricarditis)

CREST $

"Variant of Scleroderma"

- **C** Calcinosis.
- **R** Raynaud's ph.
- **E** Esophageal dysf.
- **S** Sclerodactly.
- **T** Telengectasia.

Differs from Sclero-derma in:

- +ve Anti-Centromere Ab.
- ↓ Visceral involvement.

4 Criteria is enough for diagnosis (serially / simultaneously / past)

Systemic Lupus Eryth.	Rh. Arthritis
DOPAMINE RASH 1) Discoid rash. 2) Oral ulcers → painless 3) Photo-sensitivity. 4) Arhtropathy 95% 5) Butterfly rash 50%. (Malar rash) 6) Immunologic markers: Anti-DNA. (if Active) Anti-sm Ab. Anti-phospholipid Ab. 7) Neurologic ⇒ seizures psychosis. 8) ESR ↑. 9) Renal ⇒ *albumiuria > 500 mg.* 10) +ve ANA. "v. specific" 11) Serositis. 12) Hematology ⇒ ↓ RBCs –WBCs – Platelets.	**> 6wks to diff. from Rh. fever (MASR X)** 1) Morning stiffness > 1 hr. 2) Arthritis of 3 or more areas. 3) Arthritis of hand joints & wrists. 4) Symmetrical. 5) Rh. Nodules. "By biopsy" 6) + RF. 7) X-ray: (hand & wrist) • Erosions loss of j. space. • Juxta-articular osteoporosis.

Spondylo-Arhtropathies

"Sero -ve RF having similar Articular & Extra-Articular manifestations."

They include

1) Ankylosing Spondylitis
2) Reiter's Disease.
3) Psoriatic Arthritis.
4) Reactive Arthritis.
5) Entero-pathic: UC / Crhon's D.

General Features:

آه يا ظهري!
آه يا كعبي!
أنا عيني حمرة!

1) Sacro-iliits & or Spondylitis.
2) Enthesitis.
3) Uveitis.
4) Asymmetrical.
5) +ve FH (HLA –B_{27}) –ve RF.
6) Aortitis …AI. E. Nodosa.

Any pt. e Arthropathy:

"If No Lab Abnormalities … OA"

1) ESR / CRP / CBC. Uric A.
2) RF.
3) ANA.
4) X-ray on most painful j.

	Ankylosing Spondylitis	Reiter's $	Psoriatic Arthritis
➢ DEF.	Inflammatory Arthritis starting in Sacro-iliac & Spinal J. ⇒ Ankylosis of the axial skeleton.	Inflammatory Reactive Arthritis associated e: 1) non- specific Urethrititis / Cervicistis. Chlamydia) 2) Dysentery (Salmonella / Shigella/ Yesinia)	Inflammatory Arthritis in 10 % of psoriatic pts. sharing Spondylo-arhtritis.
➢ age ➢ sex	young men 15 - 40 ys. ♂ ♀ 3:1	young men 15:1 ♂ em ♀	
➢ Cl./P			
	1) Vertebral column = low back ache آه يا ظهري • LUMBAR JOINTS → LIMITED MOV. / LOW BACK ACHE. • COSTO-VERTEBRAL J. → CHEST PAIN ↑↑ BY BREATHING. 2) Enthesitis "ACHILLES TENDENTITIS": آه يا كعبي 3) Joints: ASYMMETRICAL & PERIPHERAL.	Urethritis - Conjunctivitis – Arthritis (آه يا مفاصلي – عين حمرة – البول بيحرق) 1) Asymmetrical Arthritis. 2) Enthesitis "Achilles tendentitis" → آه يا كعبي 3) ± Sacro-iliitis & Spondylitis. 4) Plantar fasciitis.	1) Asymmetric Oligo-arthritis. 2) Symmetric Poly-arthritis like RA. 3) Psoriatic nail disease with DIP joints affected. 4) Psoraiatic Sacroiliitis & Spondylitis. DIP → Spared → RA; DIP → Affected → OA Psoriasis.
	Extra-Articular Manifestations		
	fever of un-known region. (prolonged fever)	Skin: compare e Behcet's D. 1) keratoderma ⇒ 2) circinate balantis ⇒ (ulcers on glans penis) 3) buccal ulceration ⇒ (painless) D.D e Behcet's	انظر الجلدية
5) HEART	AI – Conduction defects – pericarditis.	AI – Pericarditis.	
6) LUNG	IPF		
7) EYE	Uveitis. أنا عيني حمرة	Conjunctivitis	
8) KIDNEY	Amyloidosis ⇒ Nephrotic $		

➢ Investigations for Spondylo-Arthropathies

	Ankylosing Spondylitis	Reiter's $	Psoriatic Arthritis
Blood	➢ ↑ESR – CRP – ALP & Activity ?! ➢ Anemia.	➢ ↑ESR – CRP. ➢ Anemia.	➢ Anemia. ➢ Hyper-uricmeia
Immunology	• -ve RF. • HLA B_{27}.	• -ve RF. • HLA-B_{27}	• -ve RF. ➢ Hyper-γglobinemia → ↓C_3 & C_4.
X-ray:	A) Sacro-iliac joint: "1st to appear erosion & sclerosis. B) Spine = Lumbo-Sacral • *Vertebrae* → *square shaped.* • *Disc* → *preserved.* • *Ant. longit. lig* → *calcification of the.* • *Bony bridging bet. vertebral bodies = sydensmophytes* → *bombee spine.*	A) Soft t. swelling & narrow J. spaces. B) ± Sacro-ilitis & Spondylitis. ➢ Urine ⇒ Sterile Pyuria.	A) M-T heads & Px. pharybgeal ⇒ *pencil cup app.* B) Bone Resorption ⇒ *Opera glass app.* C) ± Sacro-ilitis & Spondylitis.

➢ Treatment

	Early Diagnosis to prevent Stiffness Physio-th. Early (swimming exercise) 1) NSAID *for arthritis.* 2) Steroids a) Enthesopathy ⇒ *local.* b) Uveitis ⇒ *Systemic / topical* 3) TNF Blockers. 4) Surgery *to destruct sydenesmophytes.*	1) NSAID *for arthritis.* 2) Steroids: a) Enthesopathy ⇒ local. b) Uveitis ⇒ *Systemic / topical.* 3) Infections ⇒ *ABS.*	للعلاج انظر الجلدية **Inflammatory Bowel Disease** UC = 10-15% / Crhon's D. = 50%. **Ch. Diarrhea + Arthropathy:** • Asymmetrical poly Arthritis. • Big Joints = Knees - Ankles. • Migratory. • Non- erosive. • TTT.: NSAID + Sulpha-Salazine.

	Mixed CT disease	Behcets' D
• ***ccc. by***	*Mysotitis - Scleroderma* – SLE ± RA features	*systemic vasculitis of unknown etiology. (Viral / Auto-immune ?!!)*
• ***Cl./P***	**Gradual onset – Rare Renal affection.** **As Scleroderma** • Arthritis. • Raynaud's ph. • Oesoph. Dysmotility. **As SLE** • Skin rash. • Fever. **As Myositis** Pain & tenderness in shoulder, neck & back ms.	1) Recurrent Oral & genital ulcers on scrotum. 2) Uveitis / Retinal vasculitis → Blindness. 3) Erythema Nodosum. ➢ *Thrombo-phlebitis* → IVC Thrombosis + CRVO ➢ *Oligo-Arthritis.* ➢ *Neuro-behcet.* ***(MS like)***
• **Invest**	• +ve ANA • +ve Anti-RNP.	• No lab invest. only Pathergy test: *Abnormal reaction to ID saline inj* *→ papule & pustule in 24-48 hrs.*
• **Ttt**	• Good Response to Steroids. (Scleroderma عكس ال)	• EN & Arthralgia ⇒ Colchicine (Other uses of Colchicine) • Oral ulcers ⇒ Topical steroids. • Uveitis ⇒ Systemic Steroids.
• ***NB ... May be diagnosed as*** ***1) ...as SLE ⇒ but kidney is spared.*** ***2) .... as Scleroderma ⇒ but Good response to steroids.***		

***female 40 ys. having* DAR**

(Dyspahgia - Arthropathy - Reynaud's ph.)

1) *Scleroderma.*
2) *CREST.*
3) *Mixed CT. "Good response to Steroids"*
4) *PM / DM.*

Uses of Colchicine

1) Acute Gouty Arthritis.
2) FMF → *recurrent attacks of fever & serositis esp. peritonitis (abd. Pain) .....Amyloidosis GN (nephritic S → CRF)*
3) Behcet's D.
4) (-) Fibrogensis → *was used in (Liver Cirrhosis Alcoholic (D – Early R)*

Vasculitis

	PAN	Churg-Strauss	GCA	Wegner's Granuloma	Takayasu's D.	Kawasaki D.
Size	Medium sized.	Small sized.	Large sized.	Small sized.	Large sized.	Medium sized.
Where?!!	Systemic	Pulmonary.	Temporal / Ophth.	URT / LRT / Renal as.	Aortic arch.	Coronaries.
Age	40-50		Old age	30-40 yrs.	Young ♀	Children.
Sex	♂ : ♀ = 2:1		♂ : ♀ = 4:1		♀ : ♂ = 8: 1	
➢ Cl./P كلمة السر						
	Vascular occlusion	As PAN + BA "late onset" ⇓	1) Uni-lat. Headache (Temporal tenderness !أي ي)	RF + Haemoptysis (Wegner's - Good pasture. - TB)	Pulsless D. Aortic arch.	Vasculitis in coronaries of children
						وشه أحمر و شفايفه زي الدم
						1) Fever.
						2) Bi-lat Conj. → Red eye.
						3) lips & oral cavity → Red.
						4) Coronaries → MI.
						5) Cx. LN++
						Vascular occ in children:
						1) Sickle cell anemia.
						2) HSP.
						3) Kawasaki D. → coronary HD.
Kidney	Narrowing of Arcuate a. → ischemia → renal HTN / RF					
Skin	✓ Palpable Purpuric eruption. "vasculitis" ✓ Livedo-reticularis. "vasculitis" ✓ Urticaria..					
CNS	Stroke; Mono-neuritis complex. → Ischemic PN → foot drop & sensory loss					
Lung	Pleurisy / IPF					
CVS	Coronary vasculitis .... Angina / M					
Abd.	Mesenteric occ. → acute abdomen					
M-S	Arthropathy					

1) Wheezy chest

2) Allergic Rhinitis.

3) RPGN → proteinuria.

4) Purpura ε palpable edge.

2) Visual: AION

⇒ LOSS OF VISUAL FIELD

⇒ UNI-LAT. BLINDNESS.

3) Jaw claudication DT ISCHEMIC MASSETER MS.

Tender scalp WHILE COMBING DT ISCHEMIA.

Fundus Exam.:

1) Miliary TB → Tubercles.
2) GCA → papillitis.
3) DM / HTN / → Retinopathy
4) IEC → Rothy Spots.
5) Polycythemia → Engorged Retinal Veins

1) ENT:

- Recurrent rhinitis.
- Epistaxis.
- Sinusitis.

2) Chest: "Granuloma"

- Cough.
- Haemoptysis.

3) GN

- HTN.
- Proteinuria.
- Edema.

4) Proptosis: DD

- Grave's D.
- Wegner's.
- Histiocytosis X.

Claudication pain:

1) LL → ↓ COP (AS) As "Burger's D"
2) Jaw → GCA.
3) Arm → Takayasu's D.
4) Pseudo-claud. → lumbar stenosis.

Measure BP in LL in 3 cases:

1) Hill's sign ↑ LL > UL by 20.
2) Co-arct. ↑ UL > LL
3) Takay. ↓ UL but N. LL.

Fever + Red Eye:

1) Lpeto-spira.
2) Kwasaki D.

➢ Investigations for Vascultis

PAN	Churg-Strauss	GCA	Wegner's Granuloma	Takayasu's D.	Kawasaki D.
1) ↑ESR "always high" 2) ↓C_3C_4 / HB sAg in 30%. 3) (-ve) ANA → if +ve SLE, vasculitis. (-ve) RF → if +ve RA, vasculitis. (-ve) ANCA. 4) Eosiniphilia. 5) Biopsy. "from kidney or any affected organ"	1) ↑ESR / CRP / TLC 2) +ve ANCA 3) Eosinophilia in lung parenchyma. 4) UA → proteinurua "GN"	1) ↑ESR / CRP / TLC. 2) Biopsy from temporal a.	1) ↑ESR / CRP / TLC. 2) Eosinophilia. 3) +ve C-ANCA. (as sclerosing cholingitis)	1) ↑ESR / CRP / TLC. 2) Angiography → narrowing of BVs.	1) ↑ESR / CRP / TLC. 2) +ve Anti-endoth. ABs. 3) Echo → aneurysm.

All: ↑ESR / CRP / TLC.
↓Hb & ↑platelets.

➢ Treatment

PAN	Churg-Strauss	GCA	Wegner's Granuloma	Takayasu's D.	Kawasaki D.
Steroids + Endoxan ± Pulse Steroid ± Interferon in HB sAg.	✓	✓ Dramatic Response to Steroids قبل فوات الأوان و ينعمى	✓	✓	Never Steroids (agg. Coronary Aneurysm) 1) Aspirin. 2) IV γ globulins.

Vasculitis

- Large BVs
  - GCA.
  - Takayasu's D.
- Medium BVs.
  - PAN
  - Kawasaki D.
- Small BVs
  - 1) Churg strauss vasculitis.
  - 2) Wegener's granuloma.
  - 3) HS vasculitis = HSP.
  - 4) Cryoglobulinemia.

Vasculitis Pathology

- Immune Complex Depositin in BVs wall
  - Vascular occlusion → Ischemia "The main problem"
  - ↑↑ fragility → Bl. Tendency

	Poly Myalgia Rheumatica	HS - Vasculitis
• Cl./P	Inflammatory Myopathy • old age. • Ms. pain - tenderness & stiffness..... in px. Ms. group (shoulder - neck - back - hip – thigh ms.) • **NB** ⇒ strong relation e **GCA** ⇒ blindness.	**1) HSP:** • Arthritis. أه يا مفاصلي! • Abd. Pain ⇒ mesenteric occlusion. أه يا بطني! • painless haematuria. ادة البول أحمر ! • palpable purpura on buttocks. التوقيع طفل! **2) Serum sickness.**
• Invest	↑ESR "inflammatory"	**HSP** = ↑ IgA + Normal Complement.
• Ttt	1) no response to **NSAID.** 2) Dramatic response to **Steroids** "protective from blindness dt high relation to GCA"	Self-limited. 1) Of the cause. 2) NSAID – Steroids – immunosuppressive.

Cryo-Globulin = Circulating Ig that ppt. in vitro in Cold Temp.

Type I	Type II = Vasculitis (small vs.)	Type III
Monoclonal IgM	monoclonal IgM + Anti-IgG (RF)	polyclonal IgM + RF
B-cell disease: • Waldenstorm's. • Lymphoma. • Multiple Myeloma	HCV → MP GN	RA – SLE. – Chronic infections.
	TTT. = Interferon + Steroids. + plasma pharesis.	

Cl./P of Cryo-Gb:

- Purpura. (palpable)
- Livedo-reticularis.
- Raynaud's ph.
- Arthralgia.
- Neuropathy (weakness)
- Renal D. (GN)

DD:AIHA dt Cold Ab
⇓
hemolytic an. in Cold temp.

Gout & Hyper-urecemia

"metabolic disease dt hyper-urecemia → ppt. Urate crystals in joints & tissues ccc. by"

- ✓ Hyper-Urecemia.
- ✓ Acute Gouty Arthritis
- ✓ Chronic Tophi Gout.
- ✓ Renal Stones.

	Metabolic "↑ Uric acid production"	Renal "↓ Uric acid excretion"
1RY	1) Idiopathic. 2) HGPRT def. part of "Lesh Nyhan $" a) X-LR. b) ↑uric acid. c) Choreo-athetosis. d) MR → self mutilation. 3) G-6 Phosphatase def. • ↑UA production. • Lactic A. → ↓ UA excretion.	RTA Causes of hypo-urrecimia 1) Pregnancy. Dt ↓GFR. 2) Fanconi. 3) Xanthenuria. 4) Allopurinol
2RY	1) Tumor lysis $: →lysis of malig. cells (leukemia / lymphoma) during chemo-th →Acute hyper-uricemia >25mg/dl. →ARF. 2) Alcohol → ↑NA catabolism.	1) ARF/CRF. 2) Drugs ↓ excretion: a) Diuretics. (Lasix & Thiazides) b) Aspirin. "Low dose" c) Cyclo-sporin. 3) Lead nephropathy.

Cl/P. of Gout

Asymptomatic

→↑ Uric A. ε no Arthropathy

→ No ttt except if:

- FH of Renal Stone.
- S. UA > 11 mg/dl.
- U. UA > 1100 mg/day.

	Gouty Arthritis		Gouty Nephropathy
	Acute Gout	**Chronic Gout**	1) Tumor lysis $ ..... → ARF. 2) UA ppt. in interstitial t. → CRF. 3) Uric acid stone in Acidic urine.
Cl./P	**Joints ⇒ Arthritis = pain + R H T S.** • Rapid *onset.* • peak *after 2-6 hrs → awakes the pt. in early morning.* • Lasts for *5-14 days.* • ppt. by … *Trauma - Infection - Surgery - Diuretics.* **Initial Sites:** • 1st MTP Joint at the "big toe" = podagra. • Other: Ankle – wrist – knee – elbow. ➢ **NB** *in severe attacks → overlying skin shows crystalline cellulites → DD with Infective Cellulites.*	1) Joints → Asymmetrical. 2) Tophi deposits on • *Skin → SC deposition → may ulcerate → extrude…* • *Joints* ***"peri-articular" → radio-opaque.*** • *ear lobule.* • *extensor surface of fingers)*	
Invest.	1) ↑ S. uric acid > 7mg/dl. > 6mg/dl. 2) ↑ ESR / TLC / CRP /Temp.	1) Joint Aspiration → *urate crystals* ***(seen by polarized micro).*** 2) Joint X-ray: • *Narrow j. spaces.* • *Peri-articular erosions.* • *Tophi → soft t. swellings.*	Uric acid in urine > 1100 mg/day = over-excretion.

Treatment of Gout

Acute Attack of Gout

1) **NSAID:**
   - Indo-methacin.
   - Diclofenac.

   Diarrhea. ↔ If for pt. can't tolerate NSAID (Gastritis / Renal D.)

2) **Colchicine.** "dramatic relief of pain"
   - (-) leucocytic migration & phagocytosis.
   - ↓Chemotatctin LT B_4 for Neutrophils.

3) **Steroids.**

 # Allopurinol

Uses of Colchicine

1) Acute Gouty Arthritis.
2) FMF → recurrent attacks of fever & serositis esp. peritonitis (abd. Pain) .....Amyloidosis GN (nephritic S → CRF)
3) Behcet's D.
4) (-) Fibrogensis → was used in (liver Cirrhosis Alcoholic LD - Early B)

Long-term

Allopurinol "1st choice"

"(-) xanthine oxidase → ↓ conv. of hypo-xanthine to xanthine → ↓ Uric acid."

- **Dose:** 300 mg /d or ↓ to 100 (in old age or RF)
- **Indications:**
  1) Repeated Acute attacks of Gout.
  2) Chronic Tophaceus gout.

  "rapid ↓ in s. Uric acid at the start of ttt. → dissolve urate crystals → ppt. acute attack."

  ⇓

  So Add Colchicine "anti-inflam."
- **S/E of Allopurinol:**
  1) Allergy → HS $.
  2) Acute gouty Arthritis.
  3) Diarrhea.
  4) P. neuritis.

Uricosurics

In Gouty Kidney

"Added to Allopurinol in s. cases"

"(-) re-absorption of uric acid from PCT → ↑ uric acid secretion in urine"

⇓

Can ppt. Urate Stones

⇓

So Add:

1) Alkaline Diuresis.
2) Allopurinol to ↓ s. Uric acid.

Diet

1) Avoid excess meat.
2) Avoid Alcohol → NA Catabolism to UA.
3) Avoid Rapid Wt. reduction → LA → ↓ UA excretion.

	Osteo-Arthritis	Septic Arthritis	Osteo-Malacia	Osteo-Porosis
Def.	degenerative D. of cartilage → wear & tear → release of cytokines & GF → collagen repair + ⊕ new bone Osteophytes → irregular rough articular surface.	Medical Emergency ⇒ sever joint destruction in short time.	Qualitative defect "good mass but defective bone mineralization"	Quantitative defect "↓ bone mass e normal mineralization"
RF	**Risk factors:** 1) Wear / tear. Aging. 2) Genetic. Smoking / 3) Obesity (load on wt. bearing j. eg knee)	**Risk factors:** 1) Aging. DM & IC. 2) Pre-existing J. "RA" 3) Artificial joints.	**↓ Vit. D:** 1) ↓ Diet - Absorption. 2) ↓ Synthesis → CRF. **↓ P & normal Vit. D**	**Risk factors:** 1) .. early menopause 2) ↓ Activity & Ca. 3) Smoking / Alcohol Caffeine / Steroids.
Causes	• **1ry** → Affects DIP & PIP joints. • **2ry** → Mech. – Metabolic - Inflam. (Haemochrom. – Wilson's D.)	**"Bacteremia / Septicemia"** 1) Staph. – Strept. 2) H. influenza (G –ve bacilli)	**↓ Vit. D → Initial ↓ Ca ⇒ 2ry PTH** • Kidney → ↓ P reab., • ↑ Bone resorp. → ↑ Ca reab.	• **Type I** → post-menopausal • **Type II** → Senile osteoporosis. • **2ry** → Cushing. / RA dt bed rest. ↑ Thyroid. ↑ Steroids th.
Cl./P	1) **pain.** (↑ e activity & ↓ by rest) 2) **Morning stiffness.** (for short time < 15 mins.) 3) **Gelling ph.** Stiffness on prolonged inactivity for < 1 min. 4) **Crepitus** on mov. dt rough art. Surface. 5) **Heberden's Nodules ...DIP.** (M/C in OA) 6) **Bouchard';s Nodules ... PIP.**	**1) F A H M.** **2) Joint pain + R H T S ± eff.**	1) **Bony Aches.** آلام العظام 2) **Ms. Weakness.** و ضعف العضلات	1) **Bony Aches.** آلام العظام (Hip fractures / VC compression) 2) **Path. fracture.** و تكسير
Invest.	**All lab invest are Normal "Degenerative":** 1) **X-ray** Narrow j. space. Marginal osteophytes. 2) **MRI.**	1) **↑ TLC / ESR.** 2) **X-ray:** soft t. swelling. & articular erosions. 3) **Synovial fluid ⇒ PNL / ±ve C&S**	1) **↓ Ca & P ....(↑ in CRF)** 2) **↑ PTH & ALP - ↓ Vit. D.** ➢ **X-ray** ↓ density areas surr. by sclerotic borders **"Looser zone"**	**All lab invest are Normal** 1) **X-ray** ⇒ ↓ bone density. 2) **DEXA scan** ⇒ ↓ bone mass.
Ttt.	**Non-medical** 1) Wt. loss. 2) Exercise → Quadriceps. 3) Warm j. **Medical** 1) **NSAID → Paracetamol.** 2) **Glucosamine SO_4.** 3) **Intra-art. Steroids** (relieve pain fro 2-6 wks.)	1) **R A A A.** 2) **Drainage + Abs.** (high dose IV)	1) **Of the cause.** 2) **Vit. D + Ca** .....Oscal "$CaCO_3$" → Constipation So use Markal "Ca Acetate" 3) α -Calcidiol in CRF.	1) **Bisphosphanate "Alandronate".** Empty stomach e full glass in semi-sitting pos. for 30 mins. to avoid esoph. Ulceration (10 mg/d or 70 mg/wk.) 2) **Calcitonin + Vit. D + Ca.** 3) **Estrogen (SERM) = Raloxifen** agonist on bone only e no effect on uterus / breast.

Important Notes in Rheumatology

p. 46 Back Ache Pain

Inflammatory	Mechanical ... OA
• ↑↑ At Night. • ↓↓ by Movement.	• ↑↑ by Activity. • ↓↓ by Rest.
• ↑ ESR / CRP / TLC • +ve FH	• Normal Lab test.

p. 64 OA & RA

OA	RA
• Degenerative	• Inflammatory
• Wt. bearing	• Small joints.
• Affects DIP.	• Spares DIP.
• Gelling ph. < 15 min. Stiffness	• Morning stiffness > 1 hr.
• -ve Extra-Articular	• +ve Extra-Articular.
• Normal lab tests	• +ve Lab tests

p. 69 Inherited Disorders of Collagen

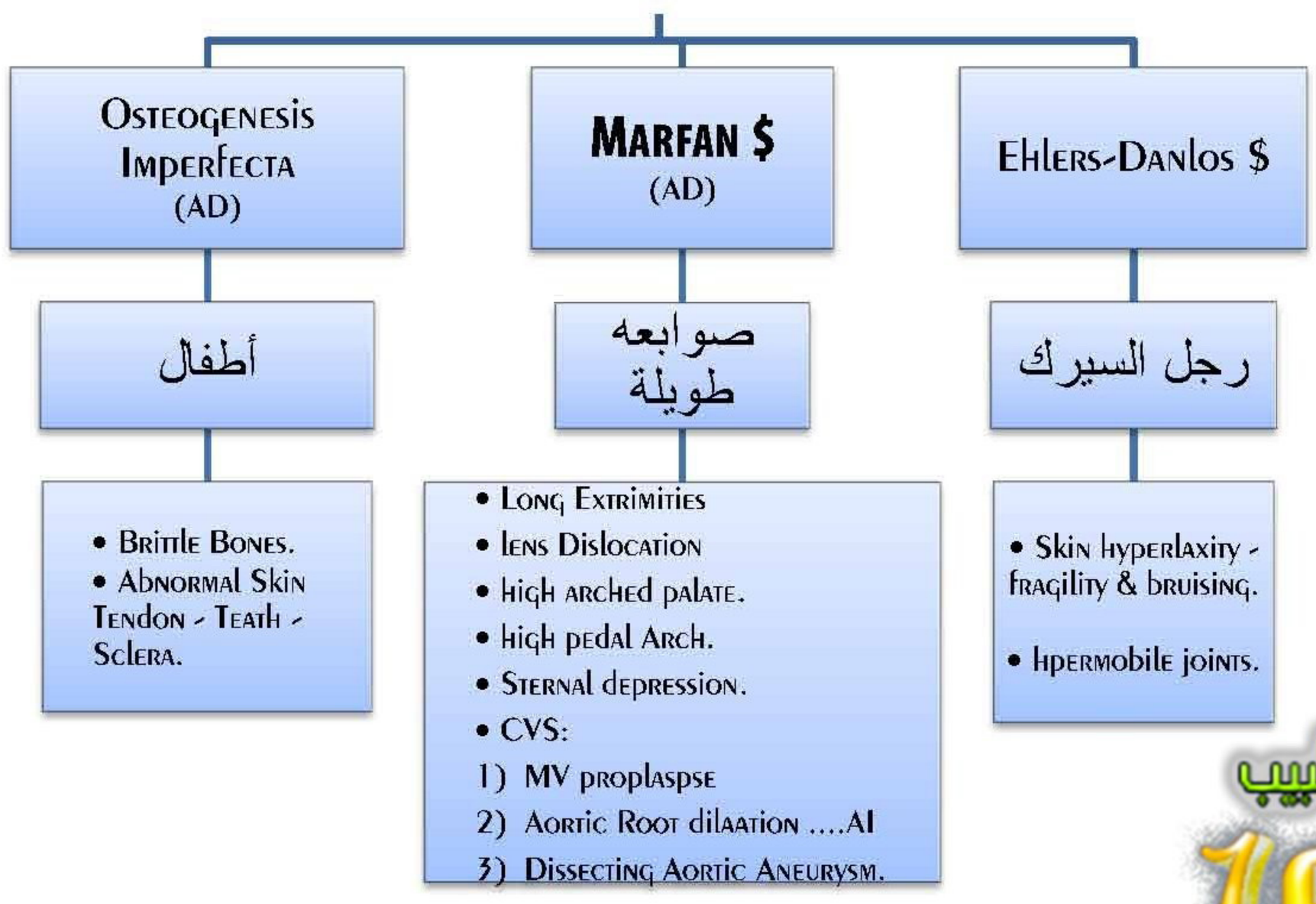

p. 41

Juvenile Chronic Arthritis

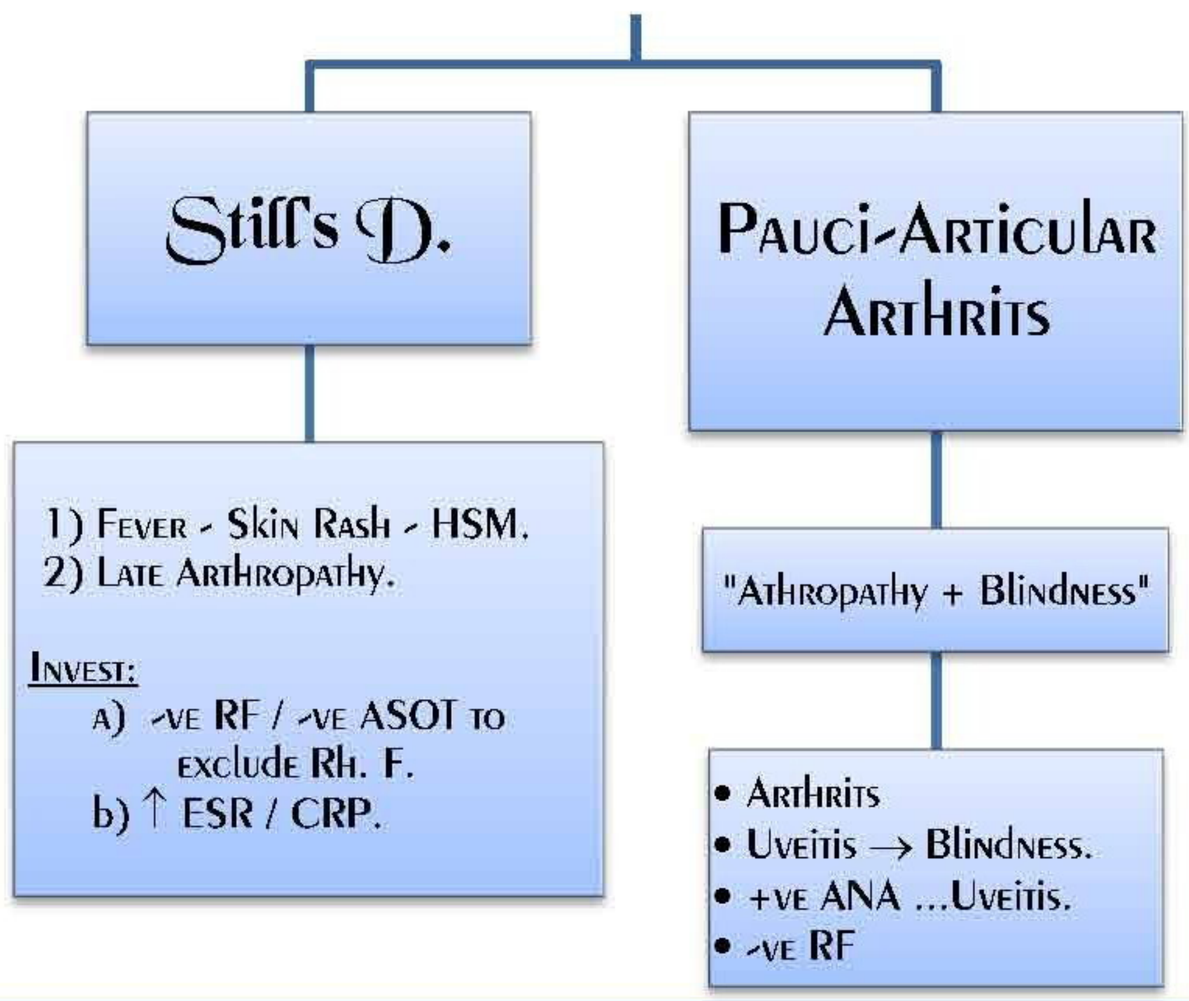

TTT. of JCA:

1) Salicylates → Reye's syndrome → so use paracetamol.
2) Methotrexate (7.5 mg/Wk) + Steroid (7.5 mg/d)
"early closure of epiphysis → so not preferred"

p. 42

Felty's $ Triad

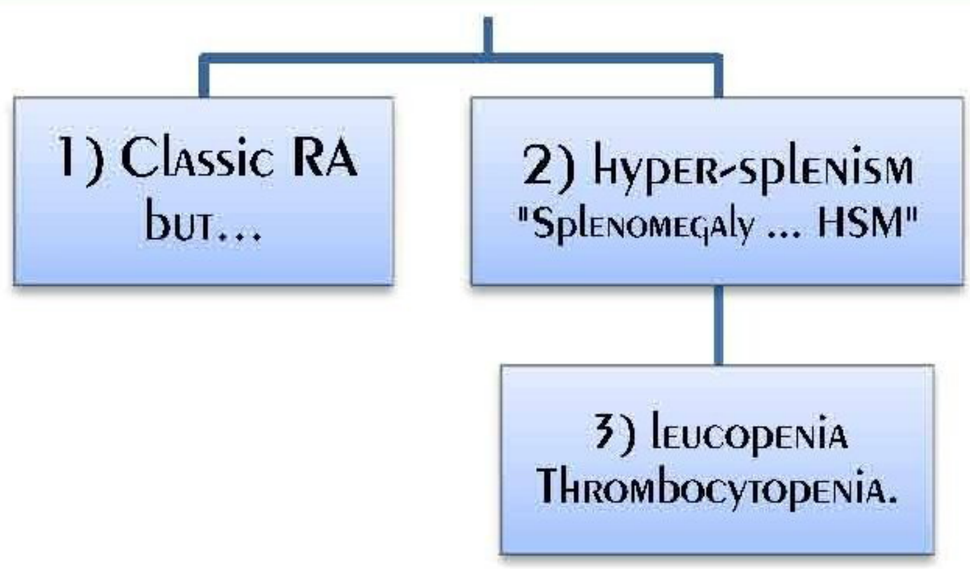

p. 42

Variants of RF:

1) Still's D. -ve RF.
2) Felty's $ +ve RF.
3) Sjogren +ve RF.

Sjogren's $

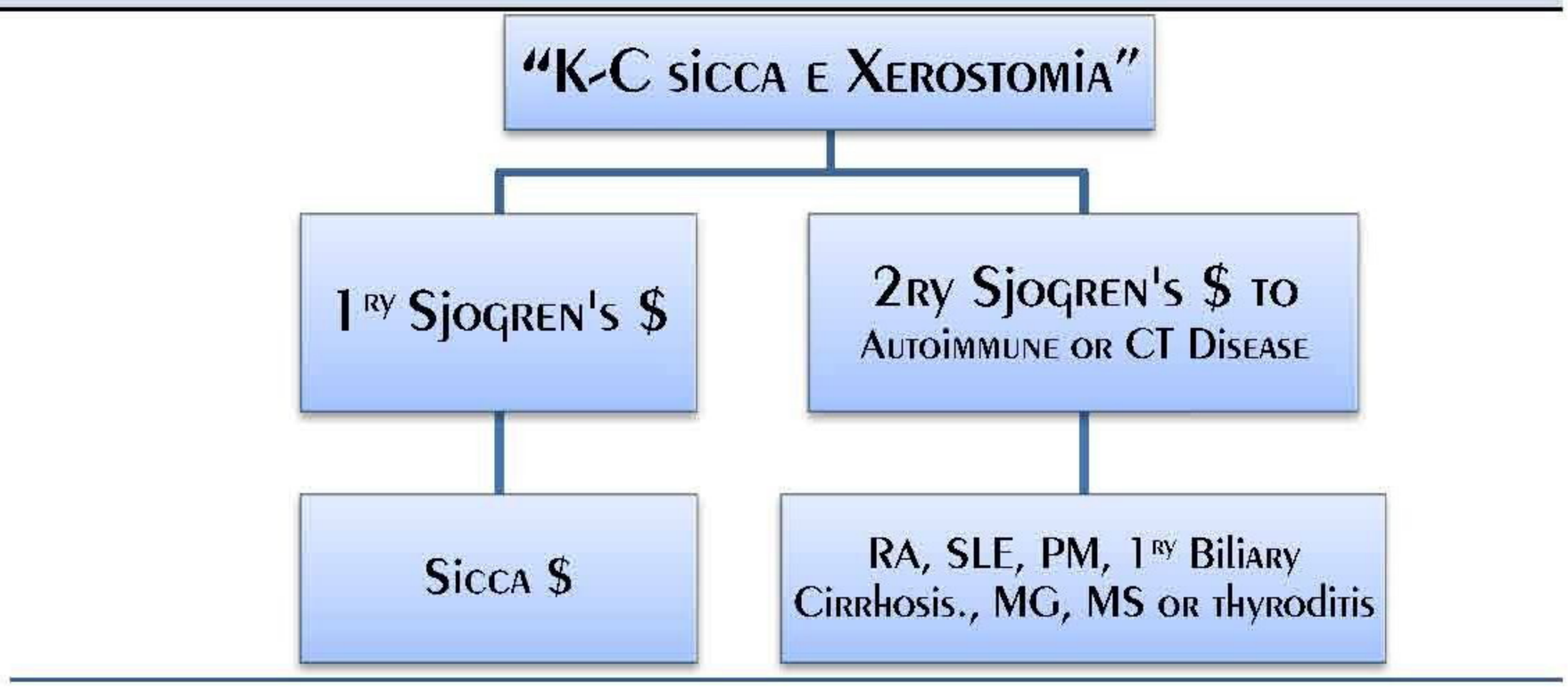

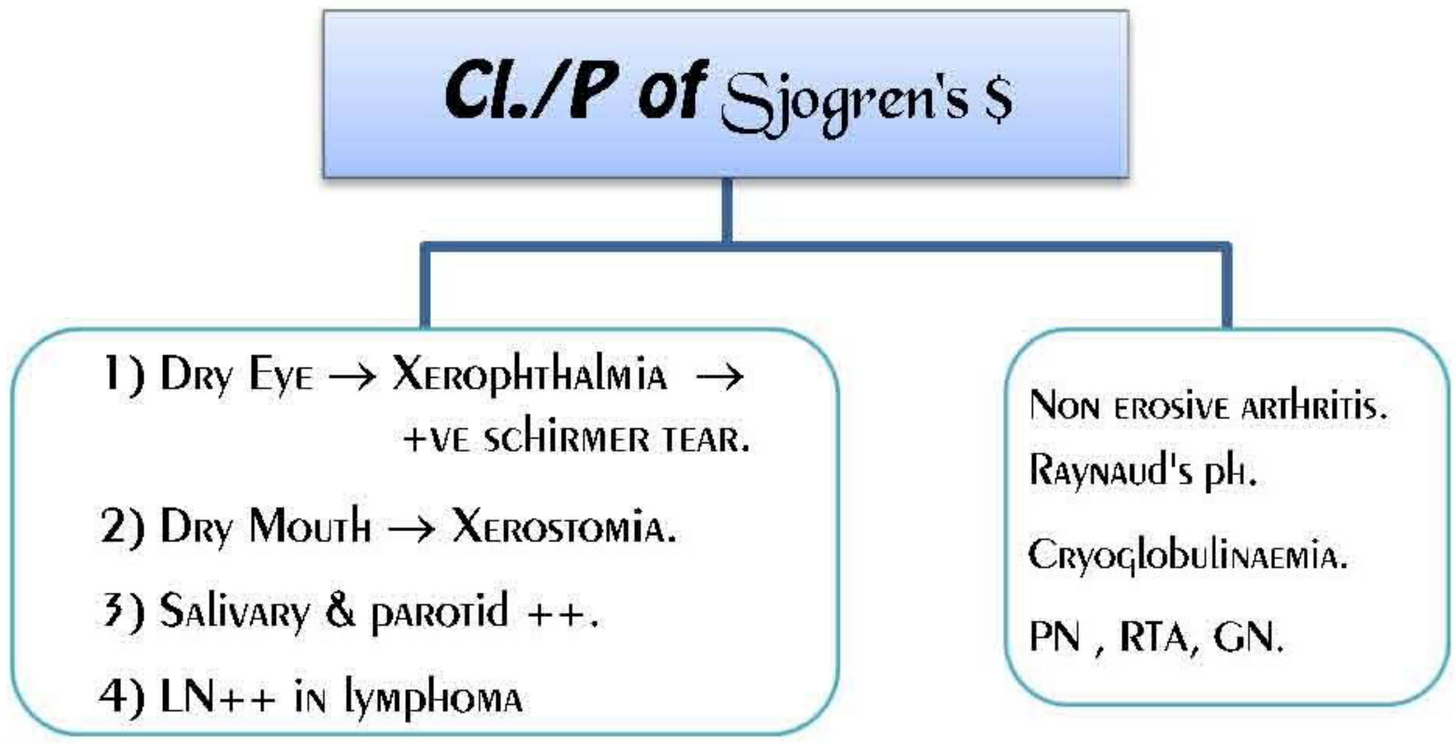

Investigations:

- +ve RF.
- +ve ANA in 80%.
- Anti-salivary duct Ab. (Sjogren's Ab).
- Anti Ro.
- Anti-parietal cell.
- Rose Bengal staining → *punctate or filamentary keratitis.*

Treatment:

1. **Dry eye:** → Artificial tears + Soft contact lense.
2. **Dry Mouth** → Sugar free chewing gum or lozenges → ⊕ saliva.
3. **Vaginal Dryness** → lubricants. (K-Y jelly)
4. **Extra glandular** → Steroids + Azathioprine.
5. **LN++** → Biopsy to exclude malignancy.

Crystal Induced Arthropathy

	Gout	pseudo-Gout	pseudo-pseudo Gout
• Crystal Type	Uric A.	CPPD "Ca++ Pyro-ph. Dehydrate"	hydroxy-Appetite Crystals.
• Sex	M > F	Equal Sex "Old age + Underlying Joint D."	F > M
• Joint	Podagra "Big Toe"	Knee "Mono-Arthritis"	Shoulder "Milwaukee Shoulder"
• TTT.	• NSAID. • Colchicine. • Steroids.	• NSAID. • Intra-Articular Steroids.	• NSAID. • Intra-Articular Steroids.
		Causes: • Haemocrhomatosis. • Wilson's D. • Hyper-PTH.	

Behcet's D. & Reiter's D.

	Behcet's D.	Reiter's D.
• Path.	Vasculitis	Sero (–ve) Arthropathy
• Red Eye	Uveitis.	Conjunctivitis.
• Ulcers	On Scrotum	On Glans penis. "Circinate balanitis"
• TTT.	• NSAID. • Colchicine. • Steroids.	• NSAID. • Intra-Articular Steroids.