HEMI-PLEGIA

paralysis of ½ of the body due to Δ tract lesion

- **from** ⇒ **Contra-lateral Cortex**
- **To** ⇒ **Ipsi-lateral** C_5 *(origin of Brachial plexus in case of SC lesion)*

Where is the lesion ?!

➢ CORTICAL

MCA OCCLUSION *"main stem"*

MONOPLEGIA AS A START DT

Wide distribution of Betz cells in area 4.

different ***Bl. Supply*** *of its areas.*

- ***Medially*** *by ACA → LL.*
- ***Laterally*** *by MCA → Face & UL*

CORTICAL SENSORY LOSS IN THE PARALYZED LIMB

⇓

as the sensory area is near to the motor area

CORTICAL MANIFESTATIONS

- **Aphasia. "Dysarthria"**
- **Conj. eye dev. to same side of lesion.**
- **Motor Jacksonian fits. "Focal epilepsy"**

conjugate eye dev. to one side

- *ipsi-lateral in cortical lesion*
- *contra-lateral in pontine lesion.*

➢ CAPSULAR

- **hemi-plegia / hypo-thesia** **(opp. side)**
- **7 - 12 CN ⇒ UMNL** **(opp. side)**

(12) Tongue dev. to *(same side of hemi-plegia)*
(7) Mouth dev. to *(same side of lesion)*

- ***homonymous hemi-Anopia.***

➢ BRAIN STEM

"doesn't appear on CT scan"

- **hemi-plegia / hypo-thesia** **(opp. side)**
- **CN ⇒ LMNL** ***According to site*** **(same side)**

crossed hemi-plegia

	MID-BRAIN	pons	MO
CN	3,4	5,6,7	9,10,11,12
pupil	Dilated	pin pointed . *"dt affection of symp. Chain"* conjugate eye deviation to opp. side.	normal
breathing	Neurogenic hyperv.	Apneustic. (post. inspiratory pause)	Ataxic br.

Hyper-ventilation:
1) DKA.
2) Uremic.
3) BS lesion.

BROWN-SEQUARD $

"SPINAL HEMI-PLEGIA"

"uni-lateral lesion above C_5"

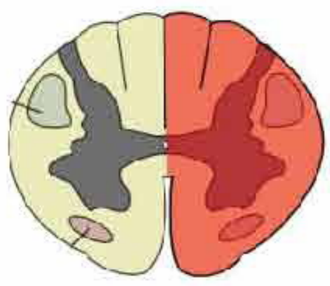

- **AT ! LEVEL**
  - **MOTOR** → **LMNL** **(same side)**
  - **SENSORY**[4] → **LOSS OF ALL SENSATIONS.** **(same side)**

  Dissociated Sensory loss
- **BELOW ! LEVEL**
  - **MOTOR** → **UMNL = hemi-plegia**[1] **(same side)**
  - **SENSORY** → **PC**[2] **loss of deep sens & Crude touch.** **(same side)**
    → **SPINO-TH.**[3] **loss of pain & Temp.** **(opp. side)**

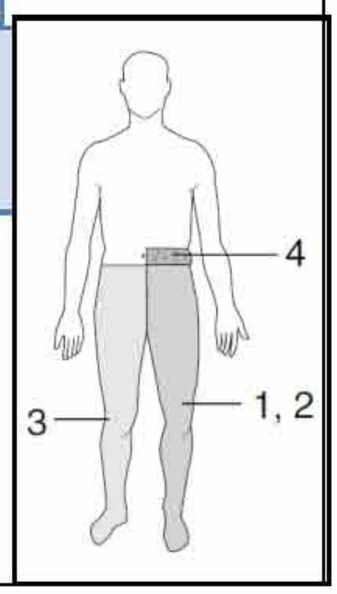

What is the lesion?!

dramatic onset
in hge & Embolism

	Inflammatory	Vascular	SOL
onset / course	**Acute / Regressive**	**Acute / Regressive**	**Gradual / progressive**
causes	Encephalitis - Abscess	cerebro-vascular stroke	Meningioma - Glioma
	Mennigial irritation 2F = **F**EVER - **F**ITS	hge & lacunar inf. "dramatic onset" → HTN - DM. Bl. Tendency. IC Aneurysm. Embolism → MVD → AF – IEC, LA Myxoma Thrombosis → 1) Atherosclerosis. 2) Vasculitis. (♀ = SLE / ♂ = PAN) 3) Thrombophilia.	↑ICT "4 Ps .. see later"

➢ stages of hemi-plegia

- TIA
  - "best time for interference"
- hemi-plegia
  - early "flaccid stage"
    - hypo-tonia, hypo-reflexia, ± coma
    - search for signs of lateralization
    - اليمين مش زي الشمال
  - late "spastic stage"
    - 1) hyper-tonia. (clasp knife spasticity)
    - 2) hyper-reflexia. (extensor plantar - loss of Abd. R.)
    - 3) (Δ weakness)
      - D > P
      - Abd > Add.
      - UL (ext. > flex.) LL (flex. > ext.)
    - 4) Sure signs of Δ tract
      - Extensor plantar - loss of Abd. reflexes.
      - Clonus = Ankle - Knee - Wrist
      - UL = hoffman - Warenburg - Finger Jerk.
    - intact Sphincters due to uni-lat Δ tract lesion

UL → flexed – Adducted.
LL → Extended – Adducted.
(رجليه زي العصاية)
⇓
Circumduction gait

Invest.	1) CT Scan if Normal ..... MRI to detect Recent or Lacunar Infarction & BS lesion) 2) EEG → focal epilepsy.
Complications of hemi-plegia	**prolonged bed rest:** 1) BED SORES. PSYCHOSIS. 2) CONSTIPATION. DVT → PULM. EMBOILSIM. 3) OSTEOPROSIS. WASTING

Treatment of hemi-plegia

(Dehydrating measures + Care of coma + Symptomatic + ...)

	Anti-viral "Acyclovir Inf."	Infarction ⇒ Anti-coag "heparin" ± Antiplatelets Hge. ⇒ conserve but if huge hematoma → devacution.	**Surgical Resection.**

PARA-PLEGIA

"paralysis or paresis of both LL"

- **SPASTIC** — DUE TO UMNL
- **FLACCID** — UMNL (FLACCID STAGE) / LMNL

PARA-plegia may be due to:

- Focal → ε level
- Systemic → No level.
- Disseminated → No level

➢ Cl./P of PARA-PLEGIA WITH LEVEL

➢ **AT ! LEVEL**
- **MOTOR** → LMNL ⇒ hypo-tonia / hypo-reflexia / marked wasting.
- **SENSORY** → LOSS OF ALL SENSATIONS.

➢ **BELOW ! LEVEL**

- **MOTOR** → **UMNL**

early flaccid stage	late spastic stage
✓ hypo-tonia.	✓ hyper-tonia. (clasp knife)
✓ hypo-reflexia.	✓ hyper-reflexia / bilat. extensor plantar
	✓ weakness … (c hemi-plegia) … Gait

- **SENSORY** → LOSS OF ALL SENSATIONS.

- **SPHINCTERIC** (IF BILAT-LESION)
  - ACUTE → RETENTION OVER FLOW.
  - GRADUAL → AUTOMATIC BLADDER.

➢ **COMPLICATIONS & TTT** = as Hemi-plegia + Neurogenic bladder (UTI / Reflux Neph. / Back pr. on kidney)

SYSTEMIC CAUSES OF PARA-PLEGIA

GRADUAL / PROGRESSIVE.

1) BI-LATERAL / SYMMETRICAL.
2) AFFECT SC BELOW UPWARDS: EARLY → PARA-PLEGIA WITHOUT LEVEL. / LATE → QUADRI-PLEGIA.
3) SELECTIVE ⇒ SPHINCTERS & ABD. REFLEXES ARE SPARED.

Other Causes of Systemic Para-plegia:

- SCD = 3 Ps (pernicious An.)
- Pellagra = SCD – PC. (pellagric rash)
- F. Ataxia = SCD + Cerebellar.
- MS & MND.

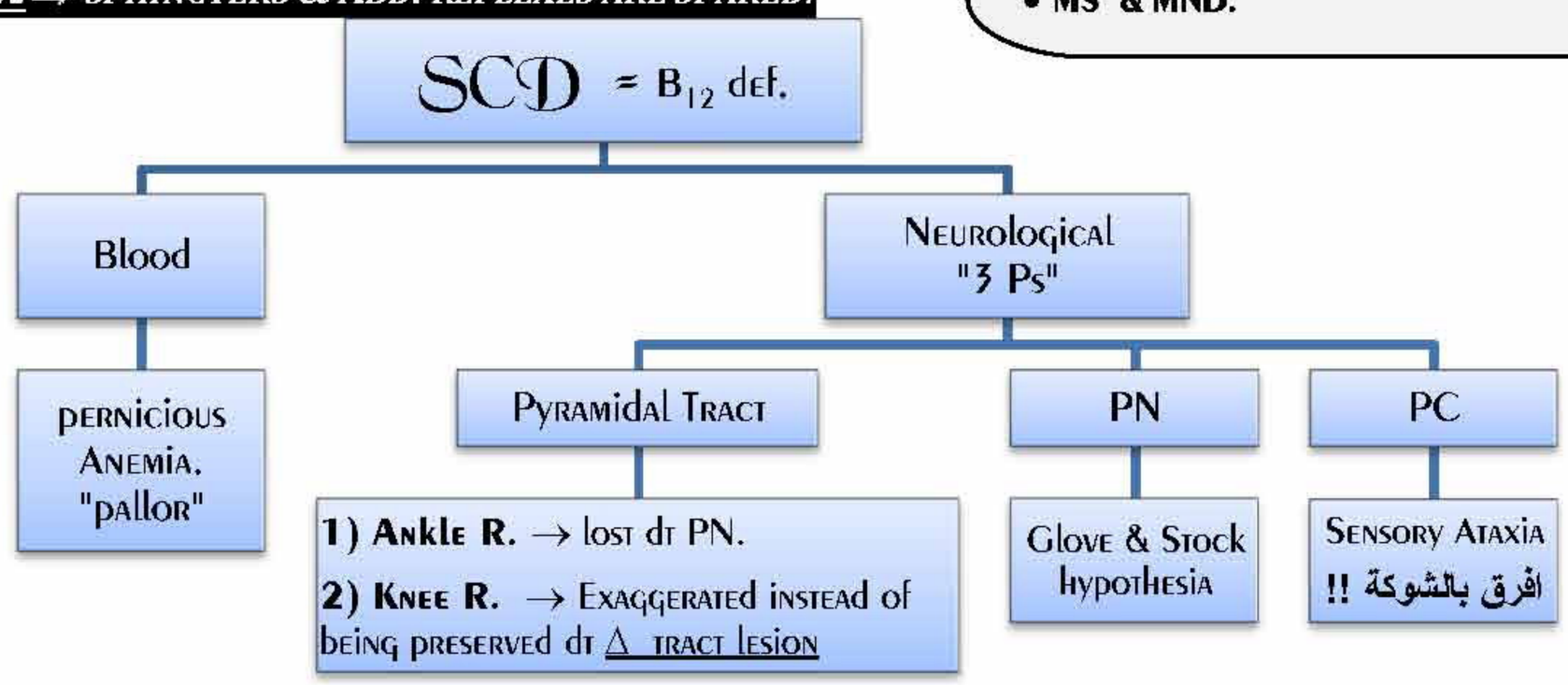

Focal SC lesion! = para-plegia e level

	Inflammatory	Vascular	compression	
onset / course	Acute / Regressive.	Acute / Regressive.	Gradual / progressive except (Trauma is acute)	
causes	**T-V Myelitis** (whole segment) Viral – Auto-immune?!	**Ant. Spinal A. Occlusion** (Thrombosis - Embolism – polycythemaia) (ant 2/3 of SC)	extra-medullary 1) Vertebral • Pott's disease. "TB" • Tumor. "MM / Osteoma / 2ry" • **Trauma "acute onset".** 2) Dural: • extra-dural → leukimic deposits. • Dural → meningitis. • Intra-dural → menigioma. 3) Disc-prolapse "MC"	intra-medullary 1) syringo-myelia: (Gliosis around the central canal of SC in lower Cx & upper Thoracic segments) 2) Tumors of SC = Glioma

fever → acute paraplegia:
1) TV Myelitis.
2) GB $.
3) Encephalitis.
4) MS.

Cl./P of Focal SC lesion

الأكلاشيه 1) At! level 2) Below! level	fever → acute paraplegia loss of All sensations. Level = multiple segments.	no fever + acute paraplegia • spino-thalamic → loss of pain & temp • PC spared → preserved crude touch. "Dissociated sensory loss"	ccc. by: good prognosis 1) Root pain — Early 2) Sphincter dist. — Late. 3) Motor — Asymmetrical 4) Sensory — Early sacral	al 3aks!!! sensory loss pattern early: jacket hypothesia only bec. PC is spared late: para-plegia (الأكلاشيه) "Diss. sensory loss"
	NB: Ascending myelopahty → Quadri-plegia. "Emergency"			
Invest	1) CT scan / MRI to exclude (compression & MS for early diag.) (with Gadolinium Enhancement) 2) CSF ⇒ Inflam. changes in TV myelitis.		1) CT scan / MRI (for early Diagnosis) 2) CSF … color → Xantho-chroma. ↑↑proteins → Spont. coagulation. ↓↓cells → cyto-albumini…..Froin $.	
Treatment	1) Steroids – ACTH. 2) Acyclovir infusion.	care of sphincters.	1) Symptomatic. 2) Surgical decompression early in Extra-medullary.	

DD of Diss. sensory loss
1) Ant. spinal A. occ.
2) Early syringe-myelia
3) Brown-Sequard$.
4) Lat. Medullay $

Neuropathy

Mono-Neuropathy	Mono-Neuropathy Multi-plex	Poly- Neuropathy
1 N. trunk in 1 limb	> 1 N. trunk in 1 limb	H. familial / Auto-immune / 2ry to
• DM • Trauma. • Compression. "Carpel Tunnel $"	السكر و العفاريت الـ4 • DM. • Sarcoidosis – Amyloidosis • PAN – Leprosy.	PMA GB $ 1) Inflam. → Viral/ Sarcoid . 2) Metabolic → DM – Uremia. 3) Drug → INH / lead / Alcohol. 4) Nutr. → SCD / Pellagra. 5) CT Disease → RA / SLE .... 6) Vascular → PAN.

Peripheral - Neuropathy

1) **Motor** — LMNL ⇒ hypo-tonia / hypo-reflexai / wasting.

2) **Sensory** → Superficial ⇒ Parathesia then Glove & Stock hypo-thesia.
→ Deep ⇒ Sensory ataxia → Vibration Lost Dx (Maleoli - Stylod process)
افرق بالشوكة !! → Preserved Px. (ASIS & Clavicle)
(While PC in Focal lesion → Loss of All deep sensation Px & Dx.)

3) **Autonomic** (diarrhea / constip. - Gastroparesis – impotence – ortho-static hypo)

Bilat. & Symmetrical LMNL Weakness
- D > P "el 3aks fil GB S" → lost ankle / preserved Knee R.
- Ext. > Flex. → Hand & foot drop. → Gait (high steppage)

Different Types of PN

	Diabetic Neuropathy	GB $	PMA
etiology	µ Angiopathy of Vasa Nervorum: • Glycosylation of collagen f. → Thick BM & Narrow lumen • ⊕ Sorbitol pathway → V. Toxic to PN.	Inflam. Demylinating D. of PN Auto-immune post –viral ?! (1-4 wks)	H. familial (AD)
onset / course	Gradual / Slowly prog.	Acute / Regressive	Gradual / Slow prog.
neuropathy +الأكلاشيه	Diabetic Triopathy	fever → then Acute para-plegia	Inverted wine shape of calf. + pes cavus.
1) Motor / Sensory	Sensory mainly • Early → Mono Neuropathy. (LL b4 UL) • Late → Poly Neuropathy.	Motor mainly but P > D • Ascending from LL – UL – Trunk. • up to Respiratory ms. "Emergency"	Motor mainly
2) Autonomic	✓	✓	✓
3) CN	"ocular" 3 4 6 → Diplopia	7 bi-lateral	

Treatment

	1) Control bl. sugar. 2) Vit. B complex. 3) CBZ for s. parathesia. (or Gana-pentin)	1) Plasma-pharesis. "choice" 2) IV γ globulins. 3) Steroids ?! Invest. = CSF → Cyto-alb. Diss. EMG / NCV.	

DD of Bi-lateral VII paralysis
1) Bell's palsy.
2) GB $
3) MS.
4) Sarcoidosis.

Parkinsonism

"Degeneration of pigmented Neurons in SN & BG → ↓↓ Dopamine"

- Idiopathic
  - paralysis Agitans
- H. Familial
  - Wilson's D.
- 2ry to
  1) Atherosclerosis.
  2) Post-encephalitic.
  3) **Drugs**: Anti-Dopaminergics as Haloperidol (ttt. of Schizoph. / Mania)

No specific lab invest. is required except if Wilson's is suspected.

No sensory loss.
No weakness.
No Fasciculations
(Bradykinesia only)

static Tremors

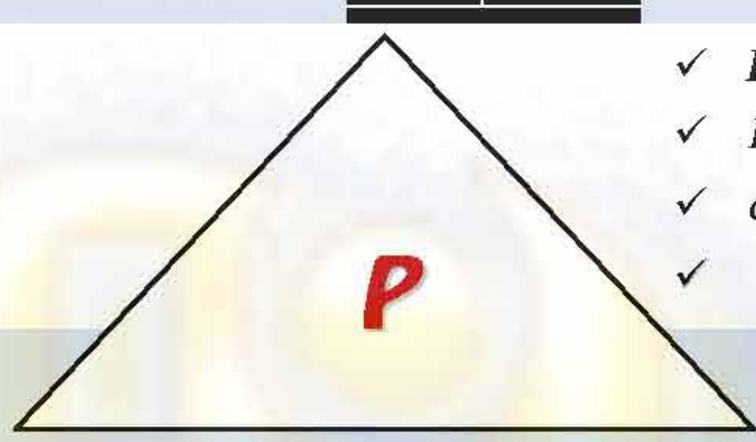

- ✓ *D > P.* *"عكس الـ chorea"*
- ✓ *Regular - Rhythmic.* *"pill rolling"*
- ✓ *coarse.* *"↑Amplitude / ↓Frequency"*
- ✓ *↑e stress & ↓during sleep.*

Rigidity "P > D"

- ***Lead pipe or cog wheel.*** *"if interrupted by Tremors"*
- ***Flex. >Ext.*** *→ gorilla like attitude.*
- *Difficulty in start of walk → short step gait. (shuffling with propulsion)*

Brady-kinesia "slow Movement"

- ***Mask*** *face.*
- ***slow*** *monotonus speech.*
- ***no swinging*** *during walking.*
- ***Can't resist*** *propulsion & retro-pulsion.*

Other Associations:

- ***Oculo-gyric Crisis*** *⇒ Sudden Spasm of of conjugate eye ms. upwards.*
- ***Glabellar reflex (7th CN) ⇒ persistent.***
- ***μ-graphia. … Postural hypotension***

Clinical Types

	post-encephalitic	paralysis agitans	Atherosclerotic
• Age	Any age	40 - 60 ys	> 60 ys
• Onset & Course	Acute / Regressive	Gradual / Progressive	Gradual / Progressive
• Cl./P	Rigidity = tremors	Tremors > Rigidity	Rigidity > tremors
• Δ signs	✓ weakness	✗	✓ weakness. "dt cerebral Ischemia"

Treatment of parkinsonism

- Bradykinesia
  - Domaine ⊕
    - L-Dopa or Sinemet
- Tremors / Rigidity
  - Anti-Cholinergic "in Drug Induced"
    - S/E = Deleirum / Dry mouth / Arrhythmia Retention of Urine … Supra-pubic dullness
- Others
  1) ββs.
  2) Amantadine ..Ms. Relaxants.
  3) Surgical adrenal t. in SN.

chorea

"invol. movement dt ↑ dopamine in caudate nucleus of BG"

	Rheumatic Chorea "Sydenham's Chorea = St. Vitus's Dance"	Huntington's Chorea
Cause	1) Major criteria of Rh. F. 2) Never e Arthritis as it occurs v. late (normal ESR)	h. familial (AD) Degenerative of BG & F. lobe
Age	5-15 ys. (♀ > ♂)	30-40 ys.
Types	1) Classic type. 2) Chorea mollis → sever hypotonia. 3) Chorea manical → sever emotional excitement. 4) Chorea gravidarum → e pregnancy. 5) Chorea gravis → interferes e sleep.	
Cl./P	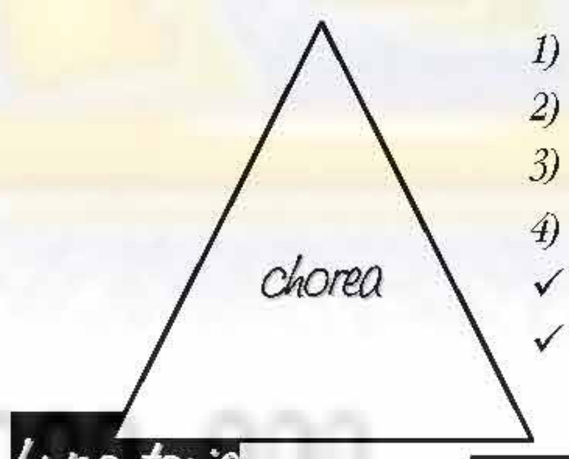 static Tremors 1) P > D. 2) sudden. jerky - sem-ipurpose 3) Irregular - Dysrythmic. 4) ↑ e stress / ↓ e sleep ✓ Grimacing ✓ Unable to keep the tongue protruded without being supported on his teeth. hypo-tonia emotional instability ✓ Scaphoid hand. ✓ Pendular knee jerk. ✓ Dancing gait.	Chorea → BG ⇓ invol. Movement Frontal lobe atrophy → Memory dist. & abnormal behavior; Dementia & psychosis
Treatment	Self limited (6 ms.) ...Add Anti-Dopamine = Haloperidol "to control symptoms during this period"	Haloperidol.

	Cl. /P	Cause	TTT.
1) Athetosis	D > P - ↑ tone – snake like mov.	BG "putamen"	Anti-Cholinergic
2) Hemi-balsimus	Sudden violent mov. Of the limb.	Sub-thalamic N.	Haloperidol.
3) Dystonia	Torsion like mov. Of one limb or trunk. Due to slow sustained ms. contraction	Wilson's / CP / Pheno-thiazines Prim Peran = Metoclopramide	1) CBZ. 2) Anti-Ch. 3) Botulinum toxin.

Transient Ischemic Attacks

"reversible acute focal neural deficit due to transient cerebral ischemia el 24 hrs."

TIA

Etiology

- **Wall**
  - spasm
    - Thrombosis / Atheroma.
    - Vasculitis (M: PAN / F: SLE)
- **Lumen**
  - Emboli "Rapidly dissolve"
    - • Poly-cythemia hyper-viscosity $.
    - • SCA.

RF

- • Old age .
- • Hypertension.
- • Smoking.
- • Hyper-cholestrolemia.
- • Collagen d.→ vasculitis
- • MVD → embolism.
- • DM - OCP.
- • ↑↑Alcohol.
- • COX 2 (-)

Cl./P of TIA

"focal neural manifest"

General

1) **Motor** → heaviness then mono or hemi-paresis
2) **Sensory** → hypo-thesia.
3) **CN** → Dysarthria. Deviation of mouth.(7-12)

if TIA Occurs in

- **V. basilar**
  - vertigo, diplopia, ataxia & syncope
- **Carotid**
  - Uni-lat.
  - Transient blindness (amarosis fugax)

Investigations of TIA

of TIA

1) CT scan → normal.
2) MRA / CTA & Duplex scan for Carotid vs. or V. Basilar system.

of RF

1) ECG, Echo
2) BS - Lipid profile.
3) ESR –Markers.
4) CBC ⇒ polycythmia ⇒ hyper-viscosity $.

Treatment of strokes

"of Rf + Care of Coma + ..."

Dehydrating measures

1) Steroids
2) Glycerin oral.
3) Mannitiol ⇒ # in HF & RF

of Infarction

1) Anti-coag. # if (bl. Tendency - hgic infarction - s. HTN - IEC)
2) Anti-platelets ⇒ Aspirin (300 mg/ d) or Dipyridamole. then Low dose Aspirin. (Clopidogrwl if Aspirin is #)
3) VD → CCB "Stugeron".
4) Piracetam (Nootropil) → improves RBCs defeomibility → improves mental function.
5) Thrombolytic Th. → TPA.

- **Carotid Endartrectomy oin ICA Stenosis**

of Hge

- Avoid drugs that interfer with clottong.
- ± Neurosurgery

Types of hgic strokes

	Cerebral hge	SAH	SDH	EDH
➢ BVs.			Rupture of Cortical Veins	MMA.
➢ Cause	1) HTN. 2) Anti-Coagulant th. 3) Rupture Cong. Or Mycotic Aneurysm.	1) Rupture of IC Aneurysm. (Berry's). 2) Rupture A-V malformation. 3) Hgic blood diseases. 4) Cerebral he → bl. reaches SA space through the ventricles.	Trivial Trauma "pass un-noticed"	Trauma with linear skull vault fracture "Wound in scalp". RF = Old age – Alcoholics.
➢ Cl./P	According to the site of hge.	Triad ↑ ICT: sudden sever geadache meningeal irritation: Neck Rigidity occurs after 12 hrs (dt lysis of escaped RBCs in CSF) cerebral VC: Focal signs eg. CN ± hemi-plegia	Fluctuation of level of consciousness. ↓ Usually asymptomatic ↓ Chronic hematoma.	Loss of consciousness for short time ↓ lucid interval ↓ Coma.
➢ Invest.	CT Scan – MRI + (CSF in SA hge → RBCs)			
➢ Treatment	As stroke	Of the cause + ... 1) Analgesics. 2) Anti-fibrinolytics. 3) Steroids to ↓ Cerebral edema. 4) Nimodipine (CCB) → VD of cerebral BVs. ➢ Radiological Intervention to (-) relapse.	Conservative 1) Control BP. 2) Anti-Epileptics. 3) Dehydrating measures.	Emergency. "Drainage through Skull burr-holes"

Infarction = Vascular occlusion

MCA "main stem"

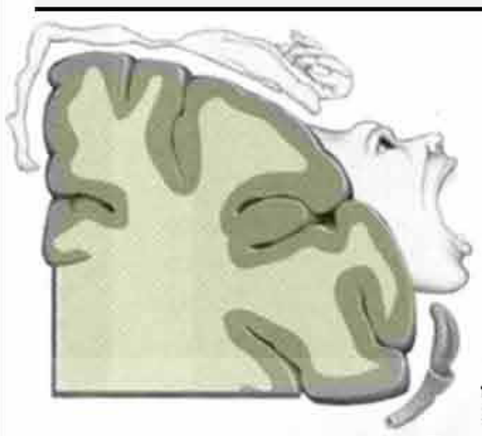

- cortical br. "lateral aspect"
  - Frontal lobe
    - **Monoplegia in Face - UL only** "Facio-brachial"
    - **Cortical sensory loss of Face – UL.**
    - **Cortical manifest.**
  - Temporal lobe
  - Parietal lobe
- capsular br. "ant. & post. limb" ⇓ Internal capsule affection
  - **hemi-plegia (face – UL – LL) (both limbs)**
  - **hemi-hypothesia**

hemi-plegia; but **UL >> LL** bec. Cortical >> Capsular weakness.

ACA "main stem"

- cortical br. ⇓ Frontal lobe "medial aspect"
  - **Monoplegia in LL only** "urinary incontinence" (bladder centre)
  - **Cortical sensory loss in LL**
  - **Cortical manifest.**
- capsular br. "ant. limb only" ⇓ Internal capsule affection
  - **Mono-plegia (face – UL only)**
  - **hemi-anashesia**

hemi-plegia but **LL >> UL** bec. Cortical >> Capsular weakness.

PCA "main stem"

- cortical br. "occipital lobe" ⇓
  - **HH e macular sparing. (Conra-lateral)**
- capsular br. "Thalamo-geniculate a." ⇓ Thalamic $ on opp. side
  - Thalamus ⇓ **Thalamic pain (burning)**
  - Internal capsule ⇓ **hemi-hypothesia**
  - BG ⇓ **Choreo-athetotic movement.**

Vertebro basilar insufficiency

POST. INFERIOR CEREBELLAR A = PICA = *"lat aspect of MO & Cerebellum"*

LATERAL MEDULLARY $ = WALLENBURGE $

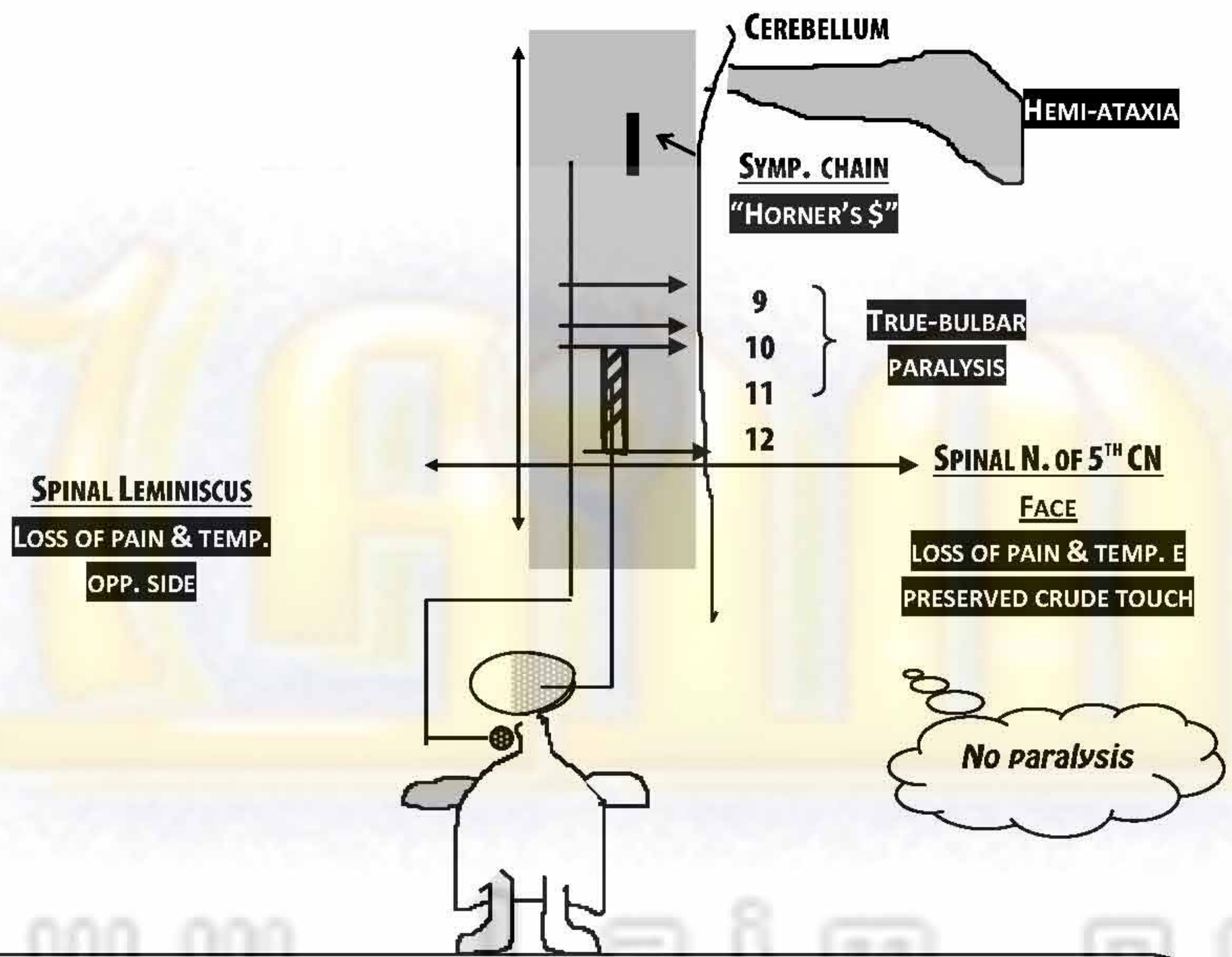

Cl./P ⇒ ***Syncope , Hicouph , vomiting , vertigo***

Contra-lateral | ***Ipsi-lateral***

spinal lemniscuss lesion
⇓
loss of pain & temperature of the body (opp. side)

- cerebellar → hemi-atoxia.
- symp. Chain → horner's $.
- 9 10 11 **LMNL** → True-bulbar palsy.
- spinal n. of 5th **CN** → loss of pain & temperature of the face e preserve crude touch

NB: PC & △ tract are intact bec. they lie in the middle of MO.

Brain Tumors = SOL

1) Meninges	Meningioma (benign) from arachnoid.
2) Gliomas	• Astrocytoma. (benign) • Medulloblastoma (malignant) "Child – Cerebellum"
3) BVs	Hemangioma.
4) Neuro-Ofibromas	Acaoustic Neuroma of 8th CN at the CPA.
5) Pituitary tumors.	(benign)
6) 1ry Cerebral Lymphomas	(malignant)
7) Metastasis	From bronchus, breast, stomach, prostate, thyroid and Kidney.
8) SOL	Tubercloma – SD hematoma – Aneurysm – Abscess.

1ry Brain Tumors → 10 %.

2ry Metastasis → 90 %.

Managment of Brain Tumors

- **Investigations**
  - **X-Ray** "of No Value"
    - 1) Signs of ↑ICT.
    - 2) Shift of pineal body.
    - 3) Ca^{++} of Tumor.
  - 1) CT Scan / MRI → ± Contrast Nephropathy.
    2) EEG→ Focal Epilepsy.
- **Treatment**
  - **Tumor**
    - Operable: Resection esp. in post. fossa tumor for fear of herniation
    - Inoperable: Radio & Chemotherapy
  - **Symptomatic**
    - Dehydrating Agents: to Control Cerebral Edema:
      1) Steroids.
      2) IV Mannitoll.
      3) Glycerine Oral.
    - Anti-Convalsants "for Epilepsy"

Brain Tumors

plateau waves:

- *Attacks of ↑ICT.*
- *Dt failure of brain auto-regulatory mech.*
- *Ppt. by sneezing, coughing.*

↑↑ ICT = 4 Ps

1) **P**ersistent Headache.
   - due top stretch of meninges.
   - never experienced b4.
   - not related to site of tumor.
2) **P**rojectile Vomiting. *(Not preceeded by Nausea dt ⊕ of CTZ in MO so not related to meals)*
3) **P**apilledema → Blurry v.
4) Brain Edema around the Tumor dt the defective BBB of the tumor's BVs.

True localizing signs

Depends on the Actual site of tumor

Irritation then Destruction

False localizing signs

- 6th CN palsy "longest IC course"
  - Mis-diagnosis as Pontine lesion.
- Ventricular Dilatation
  - 3rd ventricle
    - compression on Optic Chiasma & pituitary gl.
  - lat. Ventricle
    - pr. on Frontal lobe "Mis-diagnosis"

Foster Kennedy S:

- *Ipsi-lateral OA.*
- *Contra-lateral papilledema.*

frontal lobe	parietal lobe	Occipital lobe	Temporal lobe
Monoplegia (Opp. Side) - **Mental changes.** *(Organic psychosis)* - **Motor aphasia.** *(dom. hemisphere)* - **Conjugate eye dev.** *(same side)* - **Forced grasp reflex.** *(1st Reflex)*	• **Sensory loss** (contra-lateral) • **Motor Apraxia.** (metabolic apraxia = LCF)	**HH e macular sparing** (contra-lateral)	**no effect on taste or smell** **(Bi-lateral Represented)** **Mental changes**

Irritative lesions

Motor Jacksonian fit (Focal epilepsy)	**Sensory Jacksonian fit "Parathesia"**	**Visual hallucination** (flashes of light & field defect)	**Uncinate fit (psychomotor epilepsy)** "كاوتش يحترق"

Pituitary Tumor

↑↑ ICT

Acute pan-hypo-pituitirism
dt hge / infarction resulting from rupture of the weak tumor's BVs.
"pituitary apoplexy"

True localizing signs

⇓

Hormonal manifest

- **Chromophobe Adenoma** ⇓ ↑ Prolactin ⇓ Menstrual & Fertility.
- **Acidophil Adenoma** ⇓ Gigantism or Acromegally
- **Basophil μ Adenoma** ⇓ Cushing D. ↓ no ↑ ICT

False localizing signs

⇓

Neurological "2ry to compression"

- **Ant.** → *optic chiasma / ON.*
- **post.** → *brain stem lesions.*
- **lat.** → *optic tract.*
- **sup.** → **Hypothalamus**
  - ✓ *poly-phagia.*
  - ✓ *Disturbed body temp.*
  - ✓ *DI* • *Hypersomnia*

Brain Stem Tumors

↑↑ ICT

Crossed Hemi-plegia

- **hemi-plagia / hypothesia** ⇓ (opposite side)
- **CN "LMNL"** (same side)

Mid-brain	pons	MO
3,4	5,6,7	9,10,11,12

Cerebello - Pontine angle Tumor

↑↑ ICT

a) **8th CN** → Acoustic Neuroma (M/C) → Tinnitus & N. Deafness.

b) **Cerebellar** → Medullo-Blastoma → *Cerebellar Hemi-ataxia (same side)*

c) **Pontine Glioma** → *see before.*

d) **Meningioma.**

MULTIPLE SCLEROSIS

"Inflammatory demyelinating disease of the white matter affecting the **CNS** sparing **PNS**"

- **MOOD CHANGES** → euphoria inspite of paraplegia.
- **SPEECH** → SLURRED / STACCATO / SCANNED

LHERMITTE'S ph.
tingling in spine or limbs on neck flexion dt PC affection in Cx. region

MULTIPLE SCLEROSIS

Etiology
- AUTO-IMMUNE / Slow virus ?!

ccc. by
- AGE → YOUNG adults. (30 – 40 ys)
- ONSET → ACUTE OR SUB-ACUTE
- COURSE → REMISSION & EXACERBATION. (ONE EVERY OTHER YR.)
- DISTRIBUTION → disseminated

Cl./P of MS

BRAIN / BS / SC
- **MOTOR** ⇒ UMNL (.....plegic)
- **SENSORY** ⇒ spino-th. → superf. sens; PC → deep sens.
- **SPHINCTERIC** ⇒ INCONTINENCE

CN

• ON	Uni-lat. loss of vision
• 3 , 4 , 6	Diplopia.
• 5	V NEURALGIA.
• 7	Bi-lat 7 paralysis.
• 8	VERTIGO.
• 9, 10, 11	Pseudo-bulbar Dt UMNL

CEREBELLAR
- NYSTAGMUS / TREMORS
- ATAXIA & VERTIGO

NEURO BEHCET'S D. (MS like)
- Irido-Cyclitis.
- ORAL / GENITAL ULCERS.
- VENOUS THROMBOSIS. EG. IVC.

MANAGMENT OF MS

INVESTIGATION
1) CT SCAN / MRI.
2) VEP → Sub-clinical ON.
3) CSF → ↑ IgG

TREATMENT

of MULTIPLE SCLEROSIS

- **ACXUTE EXACERBATION**
  - Pulse Steroid (Methyl Prednisolone 1 gm / D for 3-5 days)
- **PREVENT RELAPSE**
  - β INTERFERON

SYMPTOMATIC
1) SPASTICITY ⇒ MS. RELAXANT.
2) ATAXIA & TREMORS ⇒ BUSPIRONE. (NSSRI)
3) FATIGUE ⇒ flouxetine.
4) BLADDER RETENTION ⇒ ANTI-CHOLINESTRASE.

Disc Prolapse & Spondylosis

	Acute Disc prolapse	Spondylosis
Cause	Traumatic dt lifting heavy object Tear in AF → herniation of NP.	Degenerative AF → herniation of NP. + (Osteophytes – Sclerosis – liping)
age	✓ Young. (Acute)	✓ Old. (Gradual)
Segments	✓ Lumbar (L_4 - L_5) or (L_5 – S_1)	✓ Cx & lumbar segment

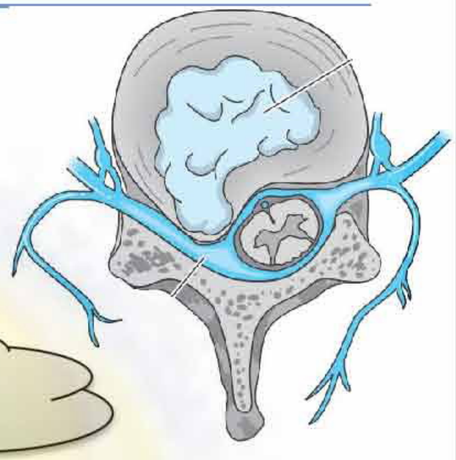

Cx. Spondylosis

- post. prolapse
  - Cord compression "Extra-medullary"
  - Focal SC lesion
    - الأكلاشيه ...
    - ± Quadriplegia if in the upper 4 Cx. vertebrae.
- Lat. prolapse
  - Roots compression
    - **Sensory** C_6
      - Radicular pain upto Sensory loss in lat. aspect of forearm.
    - **Motor** C_8 T_1
      - LMNL "weakness in small ms. of the hand"

Lumbar Disc Prolapse "Acute DP / Spondylosis"

- Cauda Equina
  - Radiculopathy affecting lumbo sacral roots dt Compresion.
    - LL Assymetrical + **Back Ache**
      - Motor → LMNL.
      - Sensory → radicular.
      - Sphincteric disturbance.
- Sciatica
  - Roots Compression Sciatic N. ($L_{4\ 5}$ $S_{1\ 2}$)
    - **Sensory**
      - hypothesia + Radicular pain upto sensory loss along back of thigh, leg, foot
      - *Meningeal irritation* dt traction on its Roots
        - can't elevate the leg up to 90° without pain
    - **Motor**
      - LMNL in ms. supplied
        - + **Back Ache**

Investigations

- CT / MRI / X-ray
  - 1) Narrowing of disc space .
  - 2) Osteophytes dt Ca^{++} of the prolapsed disc.

Treatment

- **Medical**
  - 1) NSAID.
  - 2) Ms. Relaxant.
  - 3) CBZ / Gaba-pentin.
- Physio-Therapy
  - 1) Cx ⇒ plastic Colar.
  - 2) Lumbar ⇒ Lumbar Corset.
    - Never > 3 ms. to Avoid ms. wasting.
- Surgery if (Decompression)
  - 1) Cord compression Δ signs.
  - 2) Sphincteric disturbance.
  - 3) Severe resistant pain.

Migraine

DD of Migraine:
- ✓ TIA.
- ✓ Epilepsy.

"episodic attacks of headache, usually unilateral, preceded by Aura (visual, sensory or autonomic manifestation)"

Migraine

Etiology
- psychosomatic.
- h. familial dt Genetic mutation on Ch. 19

ccc. by
- ♀ ≥ ♂, puberty,
- urban areas.
- ppt. by: Cheese, Chocolate, Alcohol, Stress, Noise, lights.

Cl./P of Migraine

paroxysmal attacks dt fluctuations of 5 HT levels in brain

↑ 5HT
VC of Intra-cranial vs.

Aura before! attack (Visual hallucination)

Flashes of light .... Scotomatas

↓ 5HT
Rebound VD of Extra-Crania vs.

Headache
- Uni-lateral.
- Throbbing ± NV.
- Engorged Temporal A.
- lasts for hrs or days

Types
1) Common M. → No aura
2) Ophthalmoplegic M. → paralysis of EOMs.
3) Basilar M. → occipital headache preceded by vertigo and diplopia.
4) Hemiplegic M. → Transient hemi-plegia for DD.

Cluster Headache
"hypo-thalamic dysfunction"

Migraine
sever attacks every 24 hrs for few wks or ms, followed by long free periods (6m - 12 m)

Autonomic Dysfunction
- Lacrimation.
- Rhinorrhea.
- Conjunctival inj.

Treatment of Migraine

During attack
Rest in dark quiet room
1) Para-cetamol.
2) Ergo-tamine ....MI / abortion / Retinal A. occ.
3) Suma-triptan.

In between attack
Avoid ppt. factors - stop OCP
1) ββ ⇒ Inhibit VD. "Indral"
2) CCB ⇒ Cinnarizine
3) CBZ ⇒ Tegretol.
4) TCA ⇒ Tryptizol.

Motor Neuron Disease

"**Systemic** degenerative diseases affecting **Motor** system **only**"

Gradual / Progressive

- ✓ Bi-lat. / Symmetrical.
- ✓ SC below / upwards. (Early / Late)
- ✓ Selective ... Sphincter spared)

- Invest. ⇒ EMG
- TTT. ⇒ symptomatic

Motor Neuron Disease

- Etiology
  - Unknown
- ccc. by
  - purely motor + Fasiculations مفتاح المسألة
    - No sensory.

Cl./P of MND

- UMN Type
  - BS
    - Cortico-Bulbar
      - pseudo-bulbar paralysis dt UMNL
  - SC
    - Cortico-Spinal
      - Lat. Sclerosis
        - 1) hyper-tonia. / hyper-reflexia
        - 2) (Δ weakness)
          - D > P
          - Abd > Add.
          - UL (ext. > flex.)
            LL (flex. > ext.)
        - 3) Sure signs of Δ tract.
        - 4) SC from below upwards. ...
- LMN Type
  - BS
    - CN Nuclei
      - True-Bulbar paralysis dt LMNL
  - SC
    - AHC "LMNL"
      - **prog. ms. Atrophy:**
        - hypo-tonia.
        - hypo-reflexia.
        - marked wasting.
        - Fasciculation.
- Mixed
  - Amyo-Trophic Lat. Sclerosis
    - UL
      - UMNL
        - hyper-tonia hyper-reflexia.
      - LMNL
        - Wasting. Fasiculations. Weakness.
    - LL
      - UMNL + LMNL "Extensor plantar"

	Pseudo bulbar palsy	True bulbar palsy
• (9,10,11,12)	UMNL = lesion	LMNL
• Palatal & ph.	Exaggerated	×
• Jaw Reflex (path. R.)	+ve if Bi-lat. lesion & above pons "origin of V. N."	×
• Quadriplegia	✓	×
• Tongue	no wasting or Fasciculation	wasting or Fasciculation

Myopathies

"Diseases of the skeletal ms. sparing the **CNS & PNS**"

DD of *purely* Motor diseases

a. Myotonia
b. Myasthenia Gravis.
c. MND
d. Parkinsonism

- **+ve FH starts at young age.**
- **Gradual / Slowly prog.**
- مشاكل **proximal**
  1) Clumsy gait.
  2) Inability to climb stairs / pick up objects from ground.
  3) weakness of **certain** ms.

1) Ms. dystrophy ⇒ **Degenerative, XL-R**	2) Inflammatory ⇒ **PMR - polymyositis.**
3) Periodic paralysis. ⇒ **AD** **(DD of MG)**	4) Drug induced. ⇒ **Malignant hyper-thermia.**
5) Inflammatory ⇒ **PMR - polymyositis.**	6) Toxic Myuopathy ⇒ **Alcohol – Thiazides – Vincitrrisine.**
7) Endocrinal ⇒ **Grave's D. – Cushing $ - hyper-PTH**	8) Myotonia - Myasthenia Gravis.

Muscular dystrophy

عضلات عامة

GENERAL Ms. WEAKNESS

- Bi-lateral / Symmetrical.
- Hypo-tonia / hypo-reflexia / marked wasting.
- **P > D**

(as LMNL but P > D)

"purely Motor" NO ....

- No sensory loss.
- No fasciculation. (to exclude MND)
- No sphincteric manif.

عضلات خاصة

- Serratus ant. & Trapezius ⇒ Winging of scapula.
- Gluteus medius & minimus ⇒ Waddling gait.
- Gluteus maximus ⇒ Gower's sign.
- Extensor ms. of the trunk ⇒ Lumbar lordosis
- Abdominal ms ⇒ Pot-belly abdomen.

عضلات خاصة جدا

eg. Pectoralis heads

الوجه

Fascio - scapulo - humeral type

استثناءات

Pseudo-hypertrophy "Duchene"

Calf ms in LL & Deltoid ms in UL

Clinical Types of Ms. Dystrophies

- **UL > LL**
  - Shoulder Girdle Type
    - Scapulo-humeral
      - Erb's "AR"
    - Facio-Scapulo humeral
      - Landouzy "AD"
- **LL > UL**
  - Pelvic Girdle Type
    - Atrophic
    - Pseudo-hypertrophy (X-LR)
      - Duchene
      - Becker
- Rare types
  - Distal, Ocular

Onset	1st decade	2nd decade
severity	severe	mild
ECG	+ ve dr Cardiomyopathy	No
death	Early.	Delayed.
Dystrophin gene	Absent.	Mutation.

Management of Myotnia

- **Investigations**
  1) ↑ Creatine / ↓Creatinine in Urine bec. ms. can't metabolize Creatine to Creatinine.
  2) Ms biopsy
  3) EMG - CK (MM fraction especially e Duchene)
- **Treatment**
  - Vitamins, physio-th.ms.
  - Avoid Obesity.
  - Ms. Transplant.

MYASTHENIA GRAVIS

سيدة تشكو من تعب و
همدان غير معتاد بعد العمل

"NMJ disease ⇒ easy fatigue of skeletal ms. on repetition of mov. & improved by rest."

MG

Etiology
Auto-immune D.
→Thymic Ab (IgG) attacks A.ch receptors at the NMJ.

ccc. by
- age → young ♀
- onset → gradual
- course → progressive

Cl./P of MG

2D (Weakness i s..)

Diurnal variation
1) Better in the morning, (worsens e mov.)
2) Easy fatigue on repitition of mov.

Descending march
1) Ocular ms → ptosis , diplopia
2) Bulbar ms → dysphagia , hoarseness
3) UL .. L.L → (P > D)

± 2T (Association)
Thyro-toxicosis or Thymus ++

Thymoma
1) Mediastinal $
2) pure Red cell aplasia.
3) MG

Investigations

Routine Invest.
to exclude other causes of fatigue:
1) CBC.
2) LFTs & KFTs.
3) BS.
4) T_3 T_4 TSH.

Bed side Test

Induction of fatigue
Ask the pt. to count from 1 till 50 ... words become less clear.

prostagmine
improvement

for Myasthenia
1) Same as Myotonia (EMG - CPK - Ms. biopsy)
2) CT Scan Thymus.
3) Anti-ACh. Rs Abs

Treatment

Medical

Anti-Choline Esterases "combine both"

- prostegmine → rapid onset / short acting
- pyridostegmins → late onset / long acting

Abs
1) Steroids.
2) plasma pharesis. "esp. in Crisis"
3) IV Ig.

Surgery
Thymeectomy "Good Prognosis"

	Myasthenic Crises	Cholinergic Crises
• Cause	Neglecting TTT.	Excessive TTT.
• Etiology	↓↓ A. ch. at the MEP	↑↑ A. ch. at the MEP
• Cl./P.	Severe weakness Hypoventilation & RF (II)	weakness hypoventilation
• Muscarinic	×	✓ Dumbles
• Edrophonium (↑ A. Choline)	Improvement	Worsens.
• Ttt.	As before	Atropine ± ventilator

2ry Myasthenia (Eaton lambert's)	Neonatal myasthenia	Toxic Myopathy
• *para-malignant $.* • ***Improves e repetition of mov.*** • ***ccc. by:*** *Not diurnal* *Not descending* *No response to prostegmine.*	✓ ***neonate*** *of a myasthenic mother.* ✓ ***Cl./P*** *→ weak suckling & cry at birth.* ***"floppy infant"*** ✓ ***Recover*** *within 2 - 6 wks* ***TTT.: ICU + Anti-Ch. esterase + plasma ph.***	✓ Botulism. ✓ Tick paralysis. ✓ OP. ✓ AG.

Familial Periodic Paralysis (AD)

1) ***Hypo K type → CHO induced*** ***(ttt.: ↓CHO, K supplement)***
2) ***Hyper K type → K induced*** ***(ttt: Ca, ttt. Of the cause)***

Myotonia

"delayed muscle relaxation after contraction"

CCC. by ⇒ mproves by repetition of mov. - Warmth & worsens by cold

- **voluntary** → *if the pt. clenches his fist → unable to open his hand rapidly.*
- **mechanical** → *Tap thenar eminence / Tapping on tongue → contraction e delayed relaxation.*
- **Electrical** → *2-3 mAmp. Is enough to ⊕ ms. contraction..*

Types of Myotonia

	Myotonia Congenita	Myotonia Atrophica
FH	+ve FH = AD	Sporadic
onset	✓ Childhood	✓ Adult.
ms	✓ Pseudo hypertrophy	✓ Atrophy esp. of Face & Temoporalis as in Chronic LD.
Dystrophy	✓ No	✓ Cataract Baldness Testicular
TTT.	Phenytoin. "Epanutin"	

DD of Facial weakness

1) Facial paralysis.
2) Facio-scapulo – hueral.
3) Myotonia Atrophica.
4) MG.

Epilepsy

"paroxysmal attacks of electrical activity in the brain (brain arrhythmia)"
may be convulsive or non-convulsive"

sudden onset / offset free
in between attacks to diff. from
schizophrenia.

Diagnosis is based on
2 unprovoked seizures

Classification of Epilepsy

Partial or focal seizure

1) Simple partial → acc. to area affected.
2) Complex partial → psychomotor or Temporal lobe epilepsy.
3) 2ry generalized partial seizures.

1ry Generalized seizures

1) Tonic Clonic. (Grand mal)
2) Absence seizure. (Petit mal)
3) Atonic seizure.
4) Myoclonic seizure. (Metabolic as Uremia / LCF)

Status Epilepticus

1) Tonic clonic status. (Grand mal)
2) Absence status. (Petit mal)
3) Eplepsia partials continua. (focal Epilepsy)

Recurrent patterns

1) Sporadic.
2) Cyclic.
3) Reflex (musicogenic)

EPILEPSY

causes:
- Head trauma.
- Abscess.
- A-V malformations.
- Tumors.
- Cerebral inf. / he.

Idiopathic

partial = Focal

simple

no loss of consciousness
" depends on area affected"

1) **MOTOR AREA** ⇒ recurrent contraction of certain ms. (fingers, arm, face)
2) **SENSORY AREA** ⇒ parathesia, auditory or visual hallucinations.
3) **LIMBIC SYSTEM** ⇒ Deja-vu, & Jamais-vu. + sense of fear.
4) **AUTONOMIC** ⇒ recurrent abd. pain. "visceral Epilepsy"

complex

loss of consciousness
" episodes of abnormal behavior"

1) **AURA** → unusual smell. **(burning rubber)**
2) **AUTOMATISM** → stop activity + minor motor activity eg. swallowing, walking aimlessly.
3) **UN-CONSCIOUS SKILLED ACTIVITY** eg: driving car, playing music.
4) **AMNESIA** for events during seizure.

DD: Schizophrenia - Hysterical fuges.

1ry Gnerealized

Grand-mal (Tonic Clonic seizures)

Dramatic loss of consciousness
"hurt himself"

1) **AURA** ⇒ visual, auditory ….
2) **SUDDEN LOSS OF CONS → HURT HIMSELF.**
3) **TONIC STAGE** ⇒ ms. spasm e epileptic cry.
   (due to forced exp. + contracted VC)
4) **CLONIC STAGE** ⇒ so vigorous → Dislocation or fracture – bitten tongue.
5) **SLOW RECOVERY** e confusion & amnesia.
   "SYNCOPE NO CONFUSION ON RECOVERY"

petit-mal (absent seizures)

no loss of consciousness
" school failure"

1) **sudden interruption** of stream of consciousness e out being lost.
2) **ASSOCIATED** with fluttering, chewing, eye blinking.
3) **LAST FOR SECONDS OR MINUTES.**
4) **regains awareness v. quickly.**

v. frequent attacks up to 100-300 times/d
(petite mal status OR pyknolepsy)

Treatment of Epilepsy

1) CBZ. "of choice" or "GABA-pentin"
2) **Na Valproate.** "hepato-toxic"
3) Topiramate. "if resistant"

1) **Phenytoin.**
2) CBZ .
3) **Na Valproate.**

"cleft lip, palate, hypertrophy of gums – Magaloblastic An."

1) Ethuxsamide.
2) Lamotrigine.
3) **Na Vaplorate.**

3-Status Epilepticus

"prolonged repeated attacks of epilepsy without regaining consciousness in bet"

Types:

a. Grand mal

b. Petite mal.

c. Focal epilepsy (epilepsia partials continua)

TTT of Status Epileptics:

1) Hospitalization
2) Isolation of the patient in dark room.
3) Muth gag - O_2 Therapy + ETT.
4) phenytoin → valium → phenobarbitol → G. anesthesia.
5) IV Glucose 50% to exclude hypoglycemia

Drug Rules:

1) One drug is better than 2 to ↓ S/E.
2) Gradual withdrawal + Stop Anti-epileptis: if the pt. becomes seizure free for 2 ys + normal CT scan & EEG
3) Pregnancy → mono-therapy is better (CBZ – Lamotrigine) … # phenytoin.

Causes of Epilepsy (seizures)

Infant (0-2 years)
1) Birth injury
2) Acute infection.
3) Hypo-glycemia
4) Hypo-calcemia
5) Congenital malformation

Child (2-12 years)
1) Idiopathic (grand or petite mal)
2) Infection
3) Trauma
4) Febrile.

Adolescent (12-18 years)
1) Trauma
2) Drugs, alcohol withdrawal
3) Idiopathic
4) A-V malformation

Young adult (18-35 years)
1) Trauma.
2) Alcoholism.
3) Brain tumor.
4) Idiopathic.

Old Age (> 45 ys.)
1) Stroke.
2) Metabolic.
3) Alcohol.
4) Brain Tuomr.

Meningitis SEE CLINICAL PATHOLOGY

	Bacterial	TB	Viral
CA	1) Meninigio-cocci. (Epidemic) 2) Pneumococci – Strept. 3) Staph. - H. influenza.	TB	1) **Herpes.** 2) Echo-Coxachie. 3) Mumps.
Symptoms	Fever → then Headache Meningeal irritation ⇓ **2 Fs** (fever – Fits) 1) **Neck rigidity.** 2) **Back rigidity.** 3) **+ve Brudzinski:** neck flexion ⇒ flexion of both hip & knee. 4) **+ ve Kering sign:** hip flexion ⇒ sever pain & inability to extend knee. ↑↑ ICT ⇓ **4 Ps** Meningio-coccal Septicemia ⇓ Water house Freidreichson's S ↑ capillary fragility ⇓ purpura fulminans Bilat. Adrenal hge. ⇓ Acute Adrenal Failure ... Shock		

CSF exam. by LP "Bed side Test"

• Pressure	↑	↑	↑
• Proteins	↑	↑	↑
• Glucose	↓	↓	N
• Chloride	↓	Markedly ↓	N
• cells	PNLs	lymphocytes	lymphocytes

Treatment of Meningitis

	1) Outbreaks ⇒ Rifampcicin for Contacts. 2) Penicillin G ⇒ 24 million U / D. 3) 3rd G CS ⇒ Cefotaxime. 4) Staph ⇒ Vancomycin.	**Anti-TB for 1-2 yrs.** (Liver + Spleen + Meningitis = TB / Lymphoma/Leukemia)	**Acyclovir® infusion**

DD of Meningeal Irritation:

1) Meningism ⇒ meningeal irritation + absence of meningitis. (Viral / typhoid)
2) Encephalitis ⇒ CSF → ↑proteins + normal Sugar & Cl.
3) Subarachnoid hge ⇒ CSF & CT scan.

ENCEPHALITIS

mostly Viral

"inflammation of the brain parenchyma... if spinal cord is involved ⇒ encephalo-myelitis."

➢ ETIOLOGY:

1ry	2ry
• *Rabies.* • *Polio.* • *I.B. virus.*	a. ***Viral*** → *Mumps, Herpes Simplex (M/C)* ***Echo - Coxachie*** b. ***Bacterial*** → *Typhoid.* c. ***Parasitc*** → *Malaria.*

➢ *Cl./P of* ENCEPHALITIS:

1) **Fever "Flu like" → Deterioration of level of consciousness.**
2) **Neurological Manifest.:**
   - *Cerebral* ⇒ *extra pyramidal.*
   - *Cerebellar* ⇒ *Ataxia.*
   - *Brain stem* ⇒ *CN lesion + + sensory tracts)*

➢ INVEST.:

1) **CT / MRI ⇒ diffuse edema.**
2) **EEG ⇒ slow waves.**
3) **CSF exam ⇒ ↑proteins + Normal Sugar & Cl.**

➢ TREATMENT:

1) **Dehydrating measures + Anti-Convulsants.**
2) **Viral ⇒ Acyclovir.**
3) **Bacterial ⇒ ABS.**
4) **Steroids ?!! ⇒ to control brain edema.**

Cranial Nerves

	Trigeminal Neuralagia	Bell's palsy
➢ Def.	Severe paroxysmal attacks of pain along one or more of the sensory brs. of V. N.	Acute inflammation of the 7 N. Near the stylomastoid foramen.
➢ Etiology	***middle age 40 - 50 ys*** • Alcohol - D.M. • H. Z. • Aberrant loop of A. compressing its rootlets.	• Reactivation of herpes virus. • Autoimmune?! • Cold exposure ?! "Old theory"
➢ Cl./P	**Severe brief lancinating pain** • Knife-like or electric shock. • Lasts for 1-2 min. • No sensory loss	• Acute Pain behind the ear → (LMNL) • ± ↓↓ Taste on the ant. 2/3 of tongue !? • Face Numbness !?
➢ TTT.	1) Analgesics. 2) CBZ. (Tegretol) or Gaba-pentin. 3) recently Topiramate.	1) Medical → Steroids + Acyclovir 2) Physio-th. → Galvanic ⊕ of the facial ms 3) Surgical → N. Grafting + Decompression.

Facial Nerve lesion

	UMNL	LMNL
Causes	• Capsular hemi-plegia	• BS lesion. (Nucleus) • Bell's palsy. (Nerve)
lesion	• above Facial Nucleus	• Facial Nuceleus or the N. itself.
Paralysis	• Opp. side. • Lower 1/2	• Same side. • Upper & lower ½ of the face
Movements	• Loss of voluntary. mov. only.	• Loss of voluntary – Emotional.
Hemi-plegia	• Hemi-plegia same side of paralysis.	• Crossed hemi-plegia(if BS lesion)

Ataxias

"In-coordination of voluntary mov. in absence of motor weakness"

Cerebellar (Motor)	H. Familial	Sensory
1) H. Familial → F. ataxia, M. Ataxia. 2) Vascular → Cerebellar A. occlusion. 3) Toxic → Alcohol – Barbiturates. 4) Neoplastic → Medulloblastoma 5) Demyelinating disease. (MS)	Gradual / Progressive. 1) Bi-lateral / Symmetrical. 2) affect SC below upwards: • *Early* → *Para-plegia.* • *Late* → *Quadri-plegia.* 3) *Selective* ⇒ *sphincters are spared.*	Due to loss of deep sensation at any point in its pathway 1) PN → D. Neuropathy. 2) post. root → Tabes dorsalis. 3) PC →SCD, TV Myelitis. 4) Thalamus →Thalamic $. 5) medial leminscus → BS lesion.

Cl./P

1) hypotonia hyporeflexia – No weakness. 2) Incoordination: • *Nystagmus →on fixation – hz →Rapid phase toward fixing point* • *Dysdiadokokinesia – Kinetic Tremors.* • *Staccato speech – Titubation of the Trunk.* 3) Gait → Drunken gait.	F. Ataxia = SCD (3 Ps) + Cerebellar 1) P. Tract → bilateral extensor plantar. 2) PN → Glove & Stock hypothesia. 3) PC → loss of deep sensation by TF 4) Cerebellar → Intentintion tremors	1) Kintetic Tremors on closure of eyes. 2) +ve Romberg's Test 3) Stamping Gait due to deep sensory loss.

Tests

• finger to nose. • finger to finger. • finger to Doctor finger. } *Intention Tremors & Dysmetria which ↑ on closure of the eyes* • Buttoning & unbuttoning → earliest sign. • Heel to knee test. – Rebound ph.		1) finger to nose. 2) finger to finger. 3) Rhombergism. } *Normal but when pt. closes his eyes .... he can't do that.*

Speech Disorders

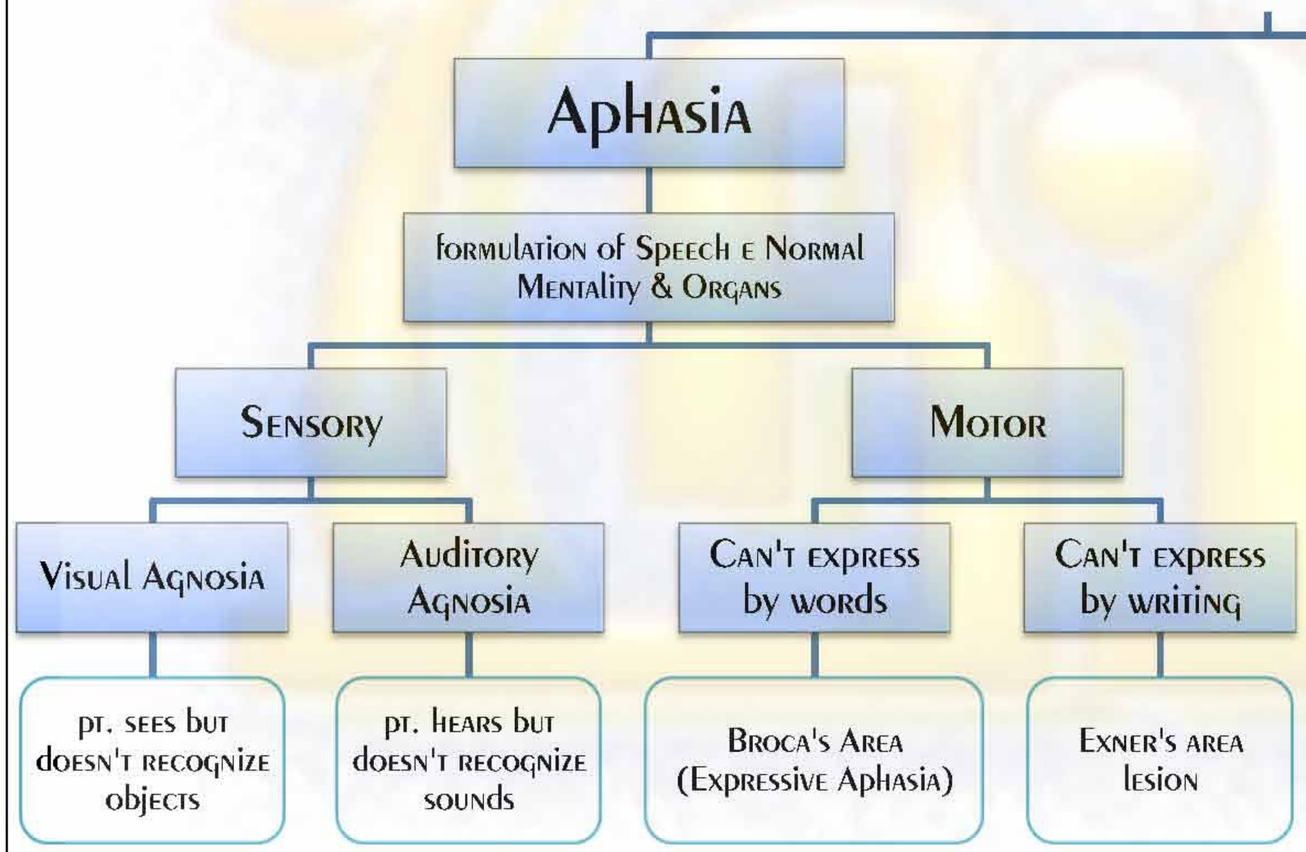

Dysarthria

problem in Articulation e Noral foramation of Speech

• **Slurred**	• Bilateral ⊿ lesion eg. Pseudo-bulbar paralysis. • <u>LMNL of CNs responsible for speech:</u> 1) True Bulbar palsy 2) Facial N. paralysis. 3) MG.
• **Stacatto**	• Cerebellar lesion. (explosive with separation of syllables)
• Scanning (Slurred Stacatto)	• Hysterical or lesion in Vocal Cords.
• **Monotonus**	• Parkinsonism.
• **Stuttering**	• Psychogenic.
• **Aphonia**	• Hysterical or lesion in Vocal Cords.

Classifications of Neurological Lesions

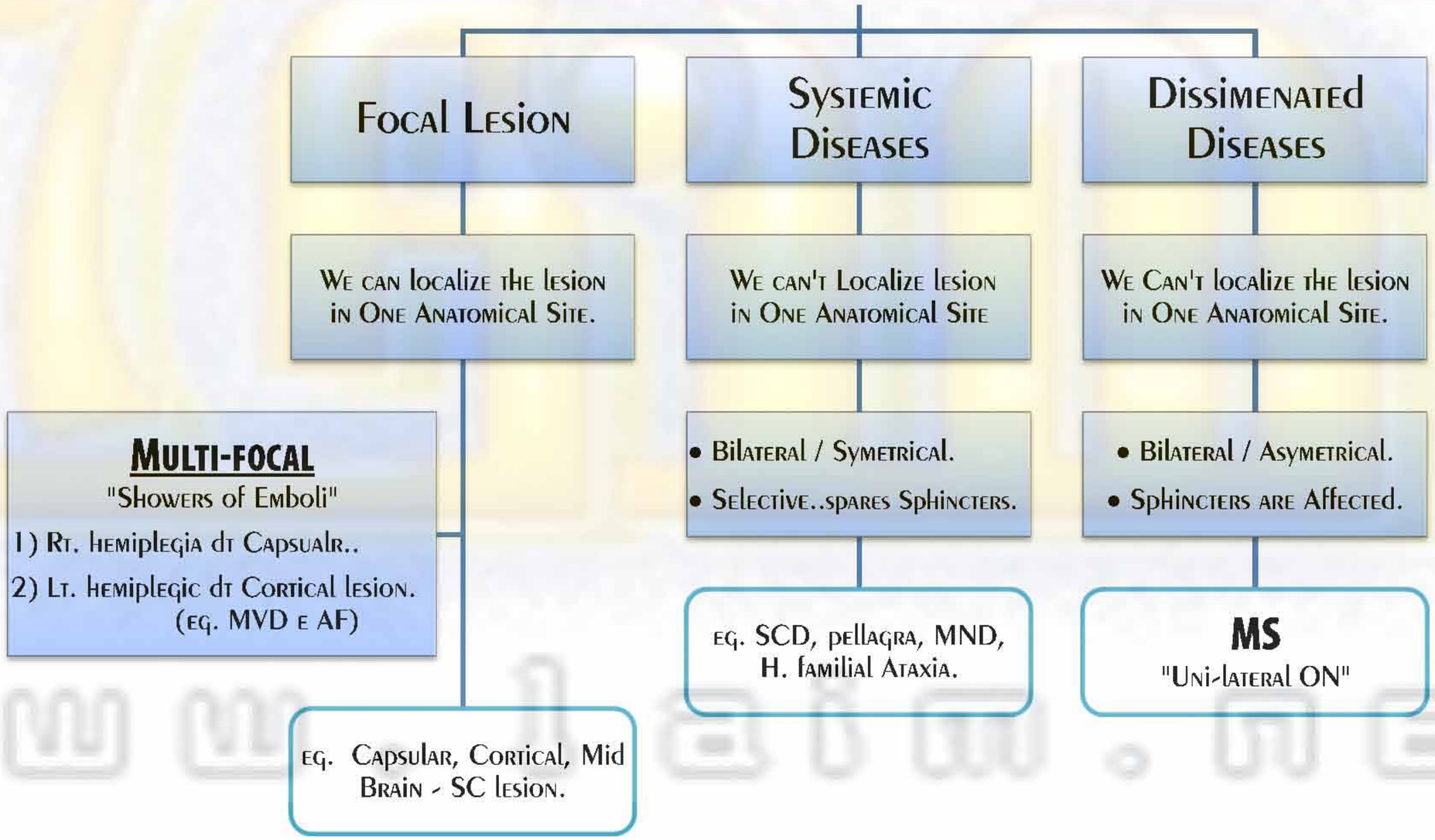

Important Notes in Neurology

p. 1	**Sub-Cortical lesion = lesion in Corona Radiata**
	• Like Cortical hemi-plegia but without cortical manifest.
p. 5	**Important $ in BS lesions**
	1) Weber's $ = Mid brain lesion – 4th CN 2) Benedict's $ = Weber's $ + Ataxia in paralyzed side. 3) Millard $ = Pontine lesion = hemiplegia + CN 3,7. 4) Foville's $ = hemi-plegia + MLB lesion → Conj. Dev. Of the eye to same side of lesion.
p. 7	**Causes of Recurrent Hemi-plegia**
	1) TIA 2) HTN enceph. 3) MS 4) post-epileptic. "Todd's paralysis" 5) Psychogenic. "conversion-diss." 6) Migrain "hemi-plegic Migraine"
	Systemic diseases
	1) SCD - Pellagra. 2) F. ataxia. 3) MND.
	DD of Dissociated sensory loss
	1) Ant. spinal A. occ. 2) Early syringe-myelia 3) Brown-Sequard$. 4) Lat. Medullay $

p. 28	DD o f Acute paralytic Illness
	1) TV Myelitis – Ant. Soinal A. occlusion. 1) GB $. 2) MG - Botulism. 3) Acute Cord Compression. (Disc prolapse)
p. 33	

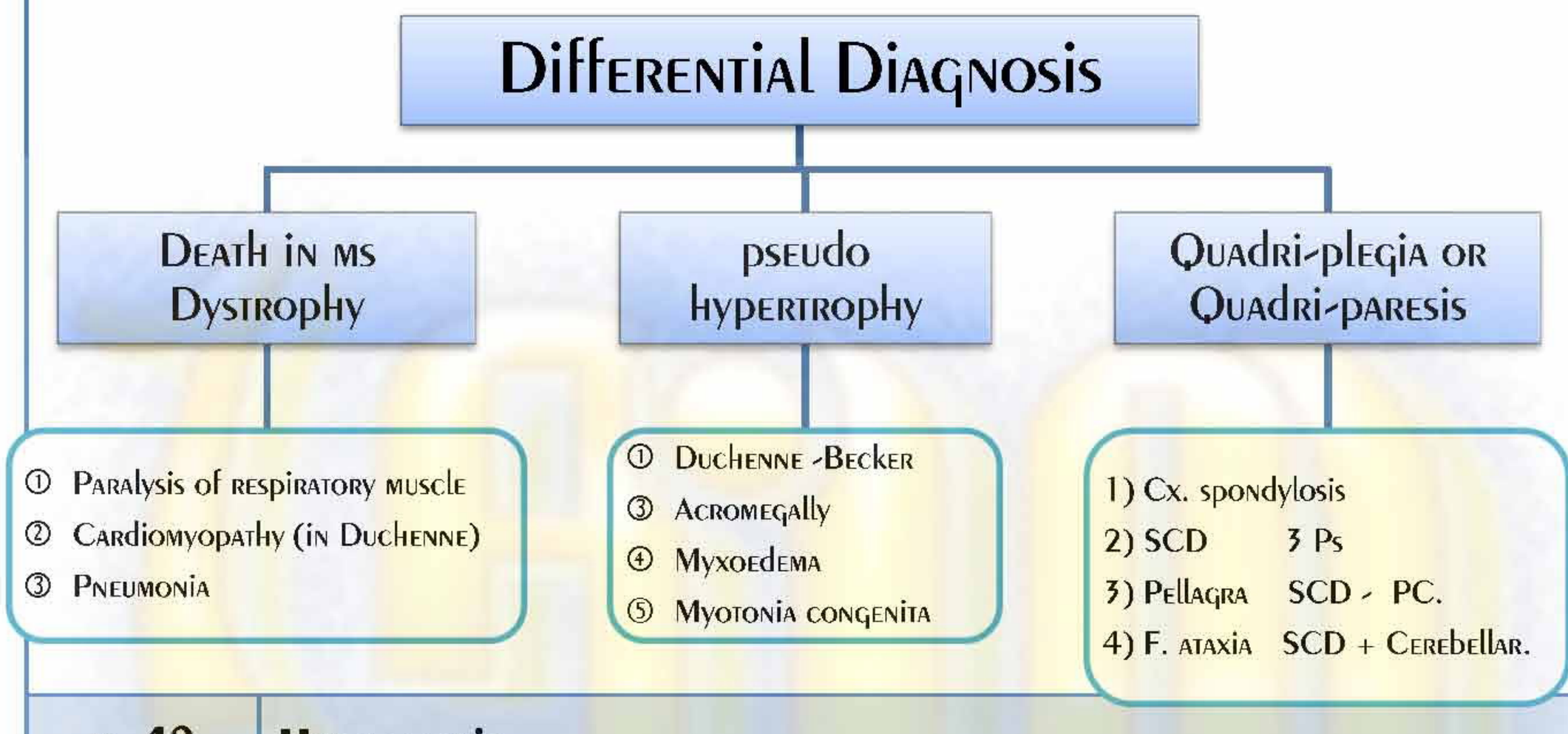

p. 42	Hyper-tonia	
	Spasticity	**Rigidity**
	• Pyramidal lesion.	• Extra-pyramidal lesion
	• Clasp knife.	• Lead pipe or Cog-wheel
	• Flexors in UL. • Extensors in LL.	• P > D. • Flexors of UL / LL / Trunk.
	• Hyper-reflexia.	• Hypo-reflexia.
p. 73		

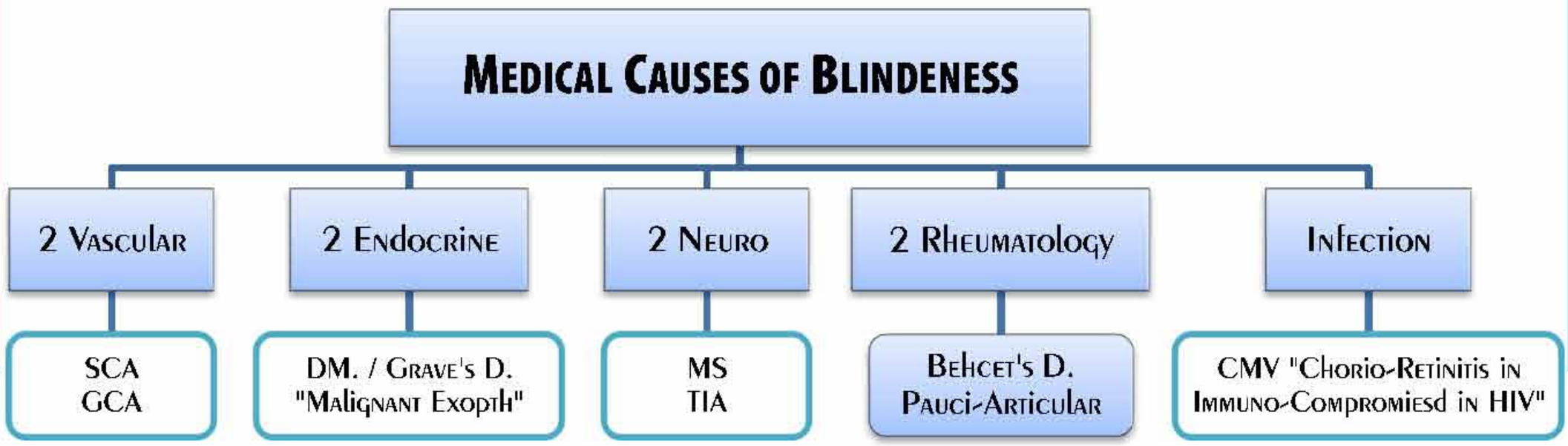

p. 73	DD of parathesia in One limb
	1) TIA. 2) Mono-neuropathy. 3) Spondylosis. 4) Focal Epilepsy. "Sensory Jaksonian fit" 5) Hypotension.
p. 75	3 Vs. Occlusion → hemi-plegia
	1) MCA "Capsular" UL = LL. 2) MCA "Main Stem" UL > LL. 3) ACA "Main Stem" LL > UL.
p. 91	DD of Non-Epileptic seizures
	1) Migraine. 2) Syncope. 3) TIA. 4) Hypo-glycemia
p. 93	DD of Meningeal Irritation

1) Meningitis	Fever → headache → Neck Rigidity.
2) SA hge	Rupture Aneurysm → sudden sever headache → then lysis of RBCs → release o f pigments → meningeal irritation after 12 hr.
3) Meningism	Irritiation e out infection. (typhoid fever)
4) Encephalitis	Deteriotation of level of consciousness.

p. 97	TB & Neurology
	1) TB & Meningitis → Neck Rigidity. 2) Pott's Disease → paraplegia. 3) Tubercoloma → SOL. 4) INH → PN dt B_6 def.

p. 98	Pseudo-Tumor Cerebri
	<u>Benign ↑ICT without SOL due to:</u> • Hyper-Vitaminosis A – OCP – pregnancy. • Invest.: Normal CT Scan. • TTT.: Steroid – Diuretics – Shunt.
p. 98	Causes of Uni-lateral proptosis
	1) Grave's Dosease. (Starts Uni-lat.) 2) CST. 3) Wegner's D. 4) Buphthalmus. 5) Histio-cytosis X.